

Oro-Facio-Digital Syndrome Type IX with Polydactyly and Multiple Intraocular Findings

Nagwa E. A. Gaboon^{1,2} and Jumana Y. Al-Aama^{1,3}

¹*Department of Genetic Medicine, Faculty of Medicine, King Abdulaziz University, Jeddah, Saudi Arabia*

²*Medical Genetic Center, Faculty of Medicine, Ain Shams University, Cairo, Egypt*

³*Princess Al-JawharaAlbrahim Center of Excellence in Research of Hereditary Disorders, King Abdulaziz University, Jeddah, Saudi Arabia*

KEYWORDS Gurrieri Syndrome. Oro-facio-Digital XI. Modes of Inheritance

ABSTRACT Oral-facial-digital syndromes are characterized by abnormalities in the oral cavity, face and digits. To date, 13 types with different modes of inheritance have been distinguished based on characteristic clinical manifestations. The researchers reported a twelve-year-old male patient with the common features of oral, facial and digital abnormalities of an OFDIX syndrome along with some unreported features. On assessment, it was found that he had a short stature and microcephaly. The patient had sparse scalp hair and alopecia areata, which is reported only in females with OFDI. He showed hands postaxial polydactyly and unilateral bifid big toe. The patient displayed extraocular manifestations along with multiple intraocular findings. There were additional CNS findings in the form of subependymal and periventricular andarachinoid tiny cysts. The arachinoid cysts were previously described in OFD I, II and III. This case overlapped with the clinical picture between OFD I, which is detected only in girls and OFD II.

INTRODUCTION

Oral-facial-digital syndromes (OFDs) are a group of heterogeneous syndromes characterized by abnormalities in the oral cavity, face and digits (Thomas et al. 2012). Thirteen sub-groups with different modes of inheritance have been described on the basis of other anomalies of the brain, eyes, kidneys and limbs (Gurrieri et al. 2007; Sarnat and Curatolo 2007; Sukarova-Angelovska et al. 2012; Adyanthaya and Adyanthaya 2015). However, the features of the various types significantly overlap, and some types are not yet well defined. The classification system for oral-facial-digital syndromes continues to evolve as researchers find more affected individuals and learn more about this disorder (Toriello 2009; Bisschoff et al. 2013). OFDS IX or the Gurrieri Syndrome (OMIM 258865) comprises the common features of oral, facial, and digital find-

ings and is characterized by the presence of intraocular anomalies in the form of retinal colobomata as a distinctive feature (Gurrieri et al. 1992).

CLINICAL REPORT

The patient for the present study is a twelve-year-old boy, the first born to consanguineous Somalian parents, with four sisters and 2 brothers. The family history is unremarkable. He was born at term following an uncomplicated pregnancy and delivery, to a healthy 20-year-old mother and a 27-year-old father, at the time of conception. The patient was referred to the Medical Genetics Clinic at King Abdulaziz University Hospital due to dysmorphism, delayed motor milestones and intellectual handicap. On assessment at the age of twelve years, he had a short stature (height was 113cm at -5 SD), microcephaly (skull circumference was 46 cm, >-3SD) and was underweight (21.2 kg; <3th percentile). The patient had sparse hair with areas of alopecia (alopecia areata) (Fig. 1A), sparse eyebrows, transverse slanting palpebral fissures, ptosis, hypertelorism and apparent microphthalmia of the left eye (Fig. 1B). There was broad nasal root and hypoplastic alar nasi with the columella extending below the nares. He had

Address for correspondence:

Nagwa E. A. Gaboon
Department of Genetic Medicine
Faculty of Medicine, (Building 9)
King Abdulaziz University
P.O. Box 80205
Jeddah 21589, Saudi Arabia
Telephone: 0096626401000 Ext. 10821
Mobile: 00966531021514/ 00201006531378
E-mail: nogaota5000@yahoo.com

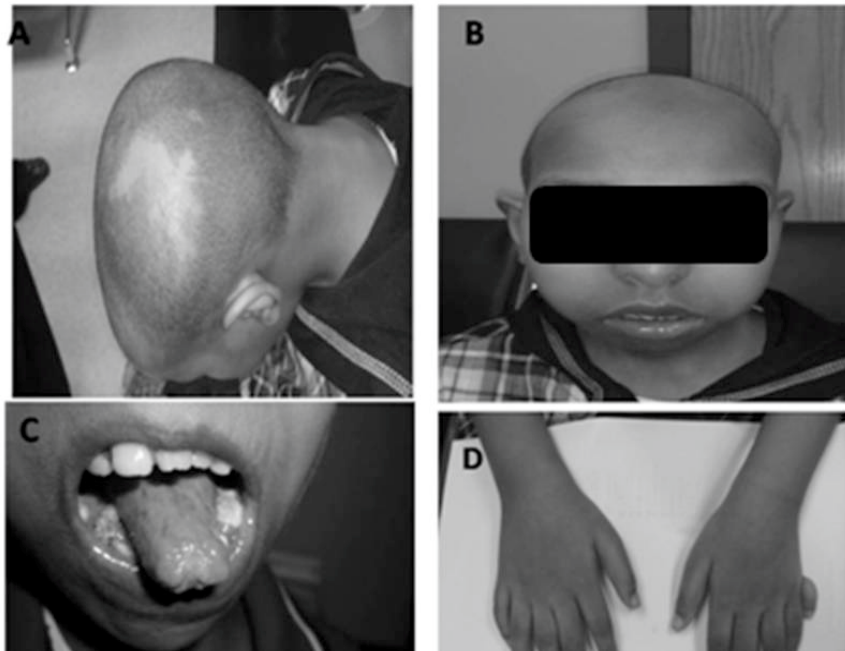


Fig. 1. Clinical features. A. Alopecia areata. B. Sparse eye brows, hypertelorism, ptosis.. C. Tongue nodules, bifid tip of tongue, and dental caries. D. Polydactyly of upper limb

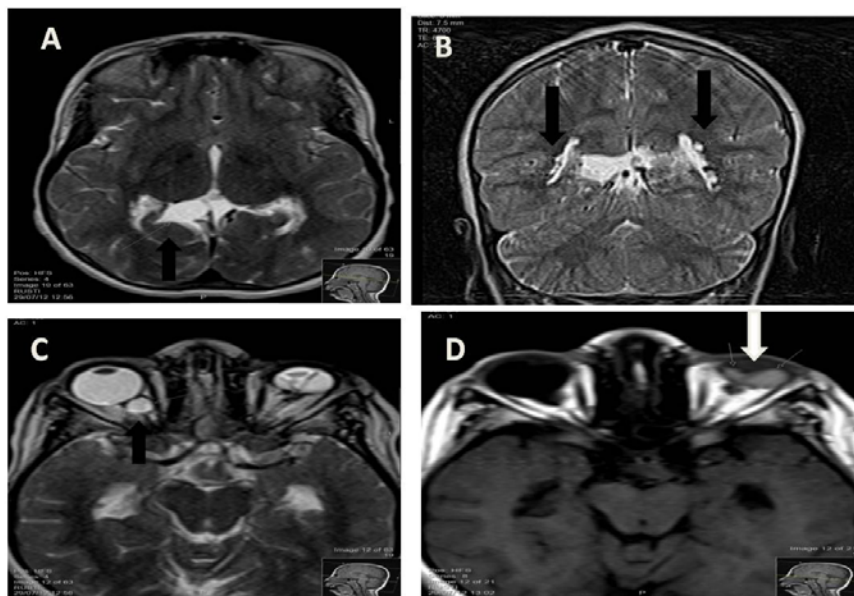


Fig. 2. MRI brain. A&B: Multiple subependymal, periventricular and arachnoid tiny cysts. C&D: Left microphthalmia and retinal detachment, right retrobulbar focal cystic lesion and optic coloboma.

posteriorly rotated ears. The mouth was held open with a prominent lower lip and a high arched narrow palate, tongue nodules with a bifid tip, irregular hypertrophic gingiva and an alveolar ridge with dental caries, together with a history of operated tongue frenula (Fig. 1C). There was retromicrognathia. The hands and feet were short with brachydactyly and upper limb postaxial polydactyly (Fig. 1D), well formed in the right hand and rudimentary on the left side. The feet showed a broad first toe on the right side and bifid on the left side. The cardiac and chest examinations were normal. Genital examination showed hypospadias. The ophthalmological examination showed right side optic nerve coloboma and left microphthalmia, cataract, and total retinal detachment.

The chromosomal study reported a normal male (46, XY). The echocardiogram and the abdominal ultrasound were unremarkable. The complete blood count, coagulation profile, urea and electrolytes, thyroid function tests, liver enzymes, were all within normal limits. An X-ray of the feet revealed a small bony projection from the medial border of the left first toe (bifid toe) and medial inclination of bilateral metatarsals. An X-ray of the hands showed post-axial polydactyly. The brain magnetic resonance imaging (MRI) showed multiple subependymal, periventricular and arachinoid tiny cysts (Figs. 2A and B). The left eye showed microphthalmia and retinal detachment, while the right eye showed a retrobulbar focal cystic lesion and optic coloboma (Figs. 2C and D).

DISCUSSION

The OFDs from a pleiotropic effect of a morphogenetic impairment variably affecting the oral cavity, face, digits and other organs. To date, 13 types have been distinguished based on characteristic clinical manifestations, (Gurrieri et al. 2007; Adyanthaya and Adyanthaya 2015). OFD IX (MIM 258865) has been previously described by Gurrieri et al. (1992) who described two sibs as type II (autosomal recessive) with eye abnormality that overlaps type VIII, which share the same findings but has a different mode of inheritance (X-linked recessive) (Gurrieri et al. 2007). Since then there were seven additional reports of type IX (Jamieson and Collins 1993; Nevin et al. 1994; Sigaudy et al. 1996; Nagai et al. 1998; Tsai and O'Brien 1999; Erickson and Bodensteiner

2007). The patient comprised the common features of oral, facial and digital abnormalities of an OFD syndrome Gurrieri type (OFD IX) (Gurrieri et al. 1992) along with some unreported features. Known features are oral, facial, and digital findings, hypertelorism, tongue nodules with bifid tip, irregular hypertrophic gingival and alveolar ridge with dental caries. In this patient there was sparse scalp hair and alopecia areata, which is reported only in OFDI (Gurrieri et al. 2007; Chetty John et al. 2010). OFDIX (Gurrieri type) is normally characterized by paucity of digital findings; hallucal duplication was the only digital anomaly previously detected in this type, while this patient showed upper limb postaxial polydactyly which have not been previously reported in Gurrieri type. Also, Erickson and Bodensteiner (2007) reported the paucity of these findings in a series of cases (Gurrieri et al. 1992; Erickson and Bodensteiner 2007). In this study, the feet showed a broad big toe on the right side and bifid on the left side, which is a common finding in OFD IX.

Ophthalmological findings, which have been reported in OFD syndromes include hypertelorism, see-saw winking and strabismus. The most common intraocular finding described in OFDS IX is retinal coloboma as a distinctive feature (Gurrieri et al. 1992) followed by optic coloboma and a single case of retinal hamartoma (Tsai and O'Brien 1999; Erickson and Bodensteiner 2007). The patient in the present study displayed more than one finding in the form of left microphthalmia, cataract, and total retinal detachment. There were also right optic nerve coloboma and a retrobulbar cyst. The presence of more than one ocular finding in one case has not been detected before.

CNS abnormalities previously detected in OFDIX included microcephaly, brain atrophy and dilated fourth ventricle (Gurrieri et al. 1992; Jamieson and Collins 1993; Sigaudy et al. 1996; Erickson and Bodensteiner 2007).

In this patient there were additional findings in the form of subependymal, periventricular and arachinoid tiny cysts. Arachinoid cysts were previously described in OFD II and III (Leao and Ribeiro-Silva 1995; Nagai et al. 1998; Gurrieri et al. 2007).

CONCLUSION

In conclusion this case showed an overlap of the clinical picture between OFD I and OFD

II. The patient showed oral abnormalities and alopecia areata which was similar to OFDI which is lethal in males as it is a X-linked dominant inheritance, however he had manifestations of OFDII in the form of polydactyly and CNS abnormalities, which are known to be less common in type IX. Also the patient had multiple eye abnormalities, which have been advocated as a specific finding of type IX. The presence of consanguinity and no findings in the parents may indicate an autosomal recessive mode of inheritance. This case describes the overlap with type of OFDII and may represent an allelic variant of OFD type IX or a new type of OFDs.

REFERENCES

- Adyanthaya A, Adyanthaya S 2015. Oral-facial-digital syndrome type 1: A review. *Bangla J MedSci*, 14: 130-134.
- Bisschoff IJ, Zeschnigk C, Horn D, Wellek B, Rieß A et al. 2013. Novel mutations including deletions of the entire OFD1 gene in 30 families with type 1 orofacial-digital syndrome: A study of the extensive clinical variability. *Hum Mutat*, 34: 237-247.
- Chetty John S, Piwnicka Worms K, Bryant J, Bernardini I, Fischer RE, Heller T et al. 2010. Fibrocystic disease of liver and pancreas; under recognized features of the X linked ciliopathy oral facial digital syndrome type 1 (OFD I). *Am J Med Genet (A)*, 152: 2640-2645.
- Erickson RP, Bodensteiner JB 2007. Oro-facial-digital syndrome IX with severe microcephaly: A new variant in a genetically isolated population. *Am J Med Genet*, 143A: 3309-3313.
- Gurrieri F, Franco B, Toriello H, Neri G 2007. Oral-facial-digital syndromes: Review and diagnostic guidelines. *Am J of Med Genet (A)*, 143A: 3314-3323.
- Gurrieri F, Sammito V, Ricci B, Iossa M, Bellussi A, Neri G 1992. Possible new type of oral-facial-digital syndrome with retinal abnormalities: OFDS type (VIII). *Am J Med Genet*, 42: 789-792.
- Jamieson R, Collins F 1993. Oral-facial-digital syndrome and retinal abnormalities with autosomal recessive inheritance. *Am J Med Genet*, 47: 304-306.
- Leao MJ, Ribeiro-Silva ML 1995. Orofaciodigital syndrome type I in a patient with severe CNS defects. *PediatrNeurol*, 13: 247-251.
- Nagai K, Nagao M, Nagao M, Yanai S, Minagawa K, Takahashi Y et al. 1998. Oral-facial-digital syndrome type IX in a patient with Dandy-Walker malformation. *J Med Genet*, 35: 342-344.
- Nevin N, Silvestri J, Kernohan D, Hutchinson W 1994. Oral facial digital syndrome with retinal abnormalities: OFDS type IX. A further case report. *Am J Med Genet*, 51: 228-231.
- Sarnat HB, Curatolo P 2007. *E-Book-Malformations of the Nervous System: Handbook of Clinical Neurology*. Series Editors: Aminoff, Boller and Swaab.
- Sigaudy S, Philip N, Gire C, Chabrol B 1996. Oral-facial-digital syndrome with retinal abnormalities: Report of a new case. *Am J Med Genet*, 61: 193-194.
- Sukarova-Angelovska E, Angelkova N, Palcevaska-Kocovska S, Kocova M 2012. The many faces of oral-facial-digital syndrome. *BJMG*, 15: 37-44.
- Thomas S, Legendre M, Saunier S, Bessieres B, Alby C, Bonniere M et al. 2012. TCTN3 mutations cause Mohr-Majewski syndrome. *Am J of Med Genet*, 91: 372-378. 7.
- Toriello HV 2009. Are the oral-facial-digital syndromes ciliopathies? *Am J of Med Genet*, 149: 1089-1095.
- Tsai PS, O'Brien JM 1999. Retinal hamartoma in oral-facial-digital syndrome. *Arch Ophthalmol*, 117: 963-965.