

Analysis of a Novel *AVPR2* Mutation in a Turkish Family with Nephrogenic Diabetes Insipidus

Güzin Fidan Yaylali¹, Daniel G. Bichet², Volkan Okur³, Klaus Levin⁴ and C. Nur Semerci^{3*}

¹*Department of Endocrinology and Metabolism, School of Medicine, Pamukkale University, Denizli, Turkey*

²*Department of Medicine and Physiology, University of Montreal, Montreal, Quebec, Canada*

³*Department of Medical Genetics, School of Medicine, Pamukkale University, Denizli, Turkey*

⁴*Department of Endocrinology, Odense University Hospital, Svendborg, Denmark*

KEYWORDS Nephrogenic Diabetes Insipidus. X-linked Recessive Disorder. *AVPR2*. mutation

ABSTRACT Congenital nephrogenic diabetes insipidus (NDI) is a rare X-linked recessive disorder associated with germline mutations of the arginine vasopressin (AVP) receptor type 2 (*AVPR2*) gene. The researchers describe a novel mutation in the *AVPR2* gene in a three-generational Turkish family with NDI. In the present report, a 22-year-old man is reported with polyuria and bilateral non-obstructive hydronephrosis. He was diagnosed with partial NDI based on the clinical phenotype, the water deprivation test and the inadequate response to 1-desamino-8-D-arginine vasopressin (DDAVP) administration. All family members who were suspected to have diabetes insipidus and/or related symptoms were studied. Sequencing analysis of the *AVPR2* gene revealed the novel missense mutation c.392 T>C; p. Leu 131 Pro:L131P (*AVPR2* gene (coding seq # NM_000054.4; prot seq # NP_000045.1). In conclusion, the proband carries a novel *AVPR2* missense mutation inherited from his carrier mother.

INTRODUCTION

The hormone arginine vasopressin (AVP) which is secreted from neurohypophysis is, in part, responsible for maintaining proper water homeostasis in response to rising plasma osmolality by means of binding to arginine vasopressin receptor 2 (*AVPR2*). *AVPR2* is in the basolateral plasma membrane of renal collecting duct principal cells, thereby inducing, after AVP stimulation, apical plasma membrane insertion of aquaporin-2 (*AQP2*) leading to increased water uptake and urine concentration. Disruption of this mutual hormone-organ relationship causes diabetes insipidus which is characterized by excretion of abnormally large volumes of dilute urine, which results in polyuria and polydipsia. Central diabetes insipidus is a result of absent or diminished antidiuretic hormone due to diseases in hypothalamo-hypophysial region whereas in nephrogenic (NDI) form there is resistance to the action of vasopressin (Fujiwara et al. 2005; Moeller 2013; Robertson et al. 2001).

NDI can be either inherited or acquired, almost 90% of congenital NDI is inherited in an X-linked recessive manner due to mutations in the *AVPR2* gene residing in the Xq28 region, while 10% is autosomal NDI caused by mutations in the aquaporin 2 gene (*AQP2*) (Anesi et al; Moeller 2013; Wesche et al 2012). NDI associated mutations in *AVPR2* result in a loss of function of V2R signaling, characterized by an inability of this receptor to generate sufficient cAMP in response to AVP. At least 200 different mutations in *AVPR2* gene have been reported (Spanakis et al. 2008) *AVPR2* mutations disrupt receptor function at various levels, such as impairment of ligand binding, defective intracellular transport and reduced receptor transcription (Fujiwara et al. 2005; Moeller 2013).

In this study, the researchers described a novel mutation in the *AVPR2* gene in a three-generational Turkish family with NDI and discussed with other mutations that were reported in the literature.

MATERIAL AND METHODS

Patients

A 22-year-old man is reported with polyuria to urology outpatient clinic. He had suffered from polyuria and polydipsia for several years. However, he did not receive any specific evalu-

*Address for correspondence:
Dr. C. Nur Semerci
Pamukkale University Hospital
Department of Medical Genetics
Doktorlar Cad. Bayramyeri
Denizli, Turkey 20020
Fax: 2136352
E-mail: nsemerci1@yahoo.com

ation. On physical examination, he had normal blood pressure and no growth failure and cognitive impairment. His weight was 73.5 kg and height was 166 cm. His urine volume was 15 litres per day. Urine specific osmolality was lower than 1.005. Renal ultrasonography and intravenous pyelography revealed a markedly distended bladder and bilateral hydronephrosis without any obstructive lesion of the ureter or urethra. He was referred to endocrinology outpatient clinic for further evaluation. His work-up revealed a daily urine output of typically 15 litres with low osmolality. His laboratory results were within the normal levels. A water deprivation test showed an inability to produce concentrated urine before and after administration of exogenous AVP demonstrating the presence of vasopressin resistant nephrogenic diabetes insipidus (NDI). Subsequent treatment with hydrochlorothiazide lowered the patient's daily urinary output by ~7 L. Addition of prostaglandin synthetase inhibitors on hydrochlorothiazide did not effect urine output. Thus the researchers discontinued indomethacine The pedigree of this family with congenital NDI is shown in Figure 1. His mother did not have any symptoms of polyuria and polydipsia. Her urine osmolality and plasma osmolality were also normal. His 51year-old, half-brother of maternal grandmother (II:11) had a history of polydipsia and polyuria since infancy. His urine volume was 20 litres per day. Urine specific gravity

was lower than 1.005. Renal ultrasonography did not show any abnormality. Treatment with hydrochlorothiazide lowered the patient's daily urinary output by ~7 L. His maternal grandmother, half-brother of maternal grandmother and niece of half-brother did not wish to participate in further investigations and therefore the researchers were not able to conduct urine and blood sampling. Person II:5 had died at age of 45 years, he had had suffered from polydipsia but there was no information about the cause of death. All clinical, laboratory and genetic investigations were conducted with the consent of the proband and selected family members.

Molecular Analysis

Peripheral blood samples were collected from proband (IV3) and relatives (III7, IV4, II4, II11, III20) (Fig. 1) DNA samples were isolated by QIAamp DNA Blood Mini Kit (Qiagen, Hilden, Germany), according to the blood and body fluid protocol using peripheral blood samples. Mutations were identified by DNA sequencing of the exons, introns, about 140 bp of the 59-untranslated region, and about 220 bp of the 39-untranslated region of the *AVPR2* gene as described previously (Bichet et al. 1994). Once a putative disease-causing mutation was found, DNA sequencing of a region of about 200 bp that included the mutation was done for other family members.

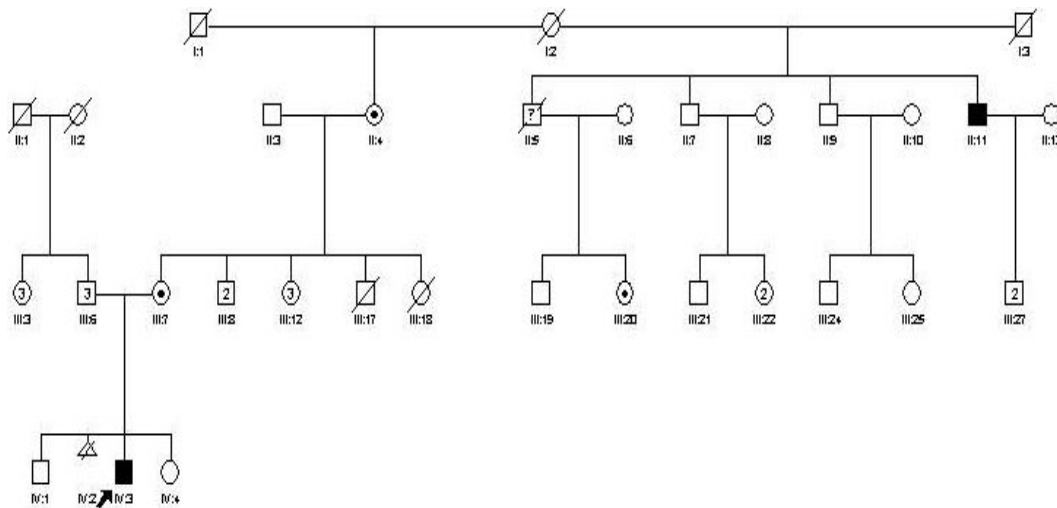


Fig. 1. Pedigree of family with NDI. Squares indicate males, circles females. Blackened symbols are affected individuals. Arrow shows the index case. Circles with dot indicates the carrier individuals

RESULTS

All family members who was suspected to have diabetes insipidus and/or related symptoms were studied and a novel missense mutation: c.392 T>C ; p. Leu 131 Pro :L131P (*AVPR2* gene (coding seq # NM_000054.4;prot seq # NP_000045.1) was detected in IV3 (proband), III7, II4, II11, III20 (Fig. 1).

No mutation was detected in proband's sister (IV4) (Fig.1). According to UniProt Consortium and Chemical Computing Group (Montreal, Quebec, Canada) the mutation (L131P) falls into third transmembran domain of protein (aa: 114-135 and aa: 110-142, respectively) (Fig. 2).

DISCUSSION

Congenital nephrogenic DI is an uncommon disorder resulting in variable degrees of resis-

tance to AVP (van Lieburg et al. 1999). In the present study, the researchers identified a novel missense *AVPR2* mutation in a 22-year-old boy, his mother, his maternal grandfather, half-brother of maternal grandmother and niece of half-brother. The boy and half-brother of maternal grandmother was characterized since infancy by the clinical symptoms of polyuria and polydipsia. Female carriers are usually phenotypically normal, like the mother of the affected 22-year-old patient of the present study .

The position of this mutation in the presented study are showed in Figure 3. The Leu-Pro exchange is the second of most commonly reported individual mutation following Arg-Cys for all missense mutations that are the leading mutation type in *AVPR2* (Spanakis et al. 2008).

The severity of the clinical symptoms of NDI varies due to the heterogeneity of the mutations causing this disorder. Female carriers are usually phenotypically normal based on X-inacti-

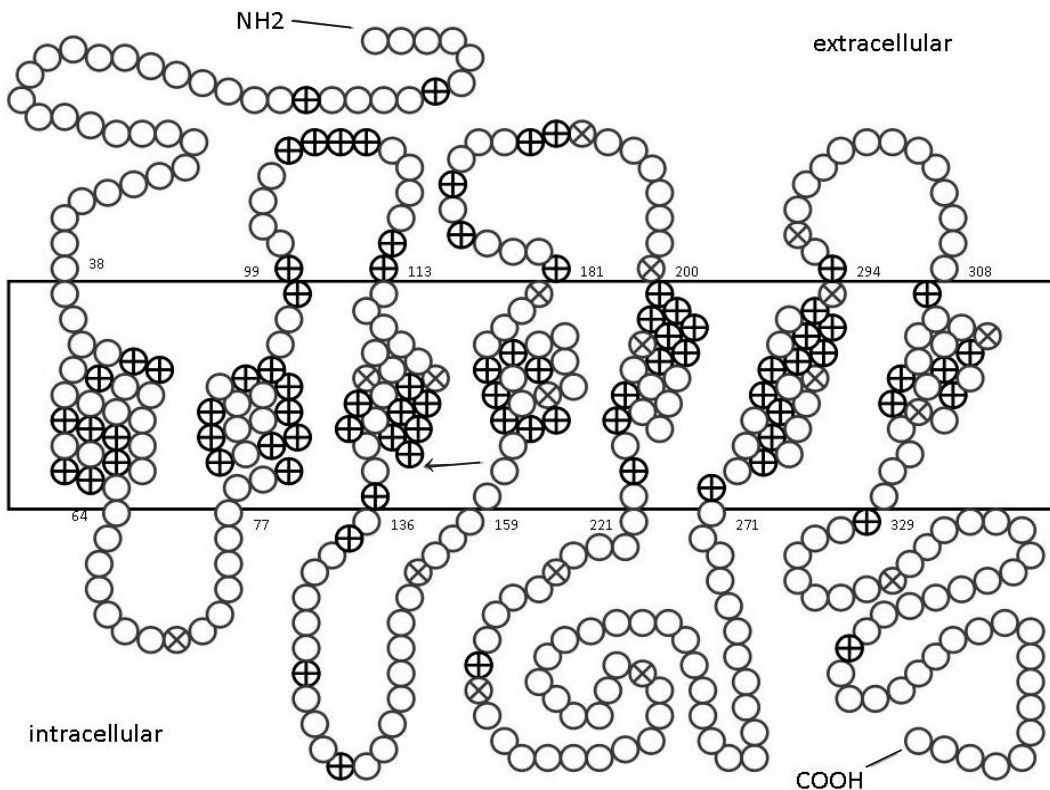


Fig. 2. Schematic view of positions of missense and nonsense mutations according to sequence annotations at www.uniprot.org. Arrow indicates our new missense mutation, L131P. Circles with plus sign represents missense mutations and circles with cross sign represents nonsense mutations. The other mutation types are not shown here

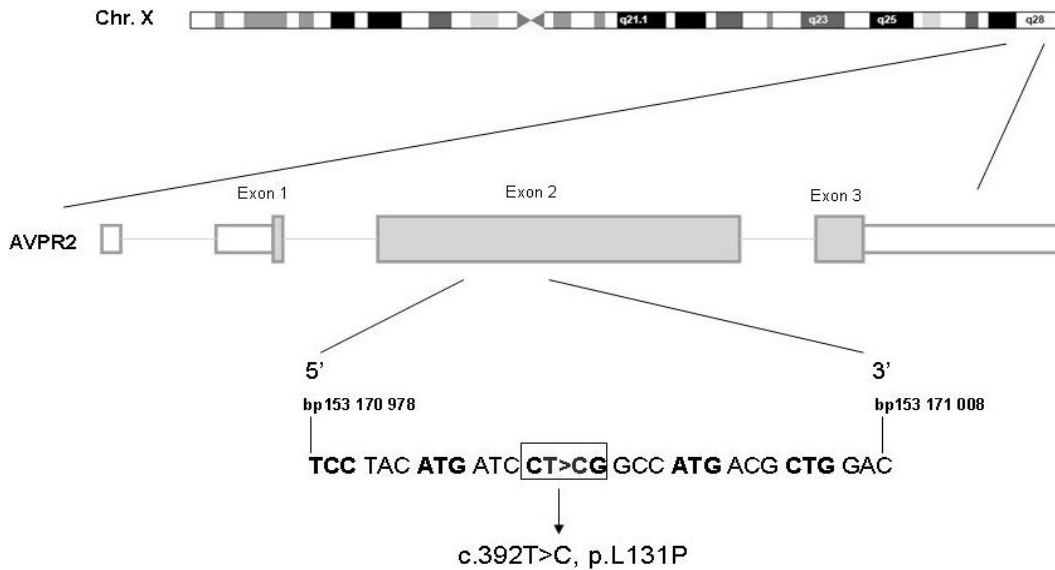


Fig. 3. Diagram of the AVPR2 gene on Chromosome X. Missense mutation in present case were indicated

vation state. Satoh et al. have found skewed X-inactivation occurring preferentially to normal alleles in female carriers who showed clinical NDI symptoms (Satoh et al. 2008). As the female carriers don't have any sign of NDI and had normal urine specific osmolality the researchers could assume that their mutant X alleles were skewedly inactivated.

In most cases, clinical symptoms usually begin within the first week of life, however, these features are often not recognized in early infancy. In childhood or early adolescence, the affected patients have recurrent episodes of severe hypernatremia due to dehydration, and they also have non-specific symptoms such as anorexia, nausea, and fever. Unless this condition is treated appropriately, the recurrent episodes of dehydration can lead to growth disturbance and mental retardation in severe cases (Nakada et al. 1990; Miyakoshi et al. 2003). Although our patient had polyuria and polydipsia since birth, he was not diagnosed with diabetes insipidus.

There are urologic complications ranging from mild ureter dilatation to severe hydronephrosis, megaureter, and megabladder that are consequences of large urine volume in patients with congenital NDI. (Zender et al. 1992; Aaronson et al. 1985; Van Lieburg et al. 1999; Birnbaumer et al. 1992). Dilatation of the urinary tract was present in 67% of the reported cases of NDI (Uribarri et al. 1993). Rarely, there

may be progressive deterioration of renal function and end-stage renal disease, probably related to voluntary retention of urine leading to bladder dysfunction. The researchers' patient had also bilateral hydronephrosis due to permanent polyuria.

The long-term management of patients with congenital NDI include sodium restriction, thiazide or amiloride diuretics and prostaglandin synthetase inhibitors, but they usually can't restore urine output. The researchers also tried thiazide diuretic, high dose desmopressin and prostaglandin synthetase inhibitor therapies for our patient. Treatment with hydrochlorothiazide lowered the patient's daily urinary output by ~7 L. Addition of prostaglandin synthetase inhibitors on hydrochlorothiazide did not effect urine output. Although his urine volume did not completely return to normal ranges it has reduced to 6- 7 lt/ day. Recently, there are some reports in which the potential of non-peptide agonists and antagonists have been found to relieve NDI symptoms for certain mutations some of which (Y128S, I130F and R137H) share similar location with our mutation (Los et al. 2010; Bernier et al. 2006). Thus, those pharmaceuticals may also be useful for our patient.

To the best of our knowledge there is not too much study investigating molecular basis of hereditary central or nephrogenic DI in Turkey. In a recent study, Duzenli et al. studied 15 Turk-

ish patients with DI, of which 9 have NDI (Duzenli et al. 2012). They have found 12 different mutations in all cohort, seven of that detected in *AVPR2* gene. Furthermore, six of those 7 mutations were also missense mutations. The researchers propose that as in their case, most of the patients with symptoms of DI either central or nephrogenic in Turkey could be overlooked. If their diseases are clinically diagnosed and molecularly confirmed the phenotype-genotype relationship of this disease may be well described.

In summary, the researchers report here a case of congenital NDI with bilateral non-obstructive hydronephrosis that were diagnosed by water deprivation tests and the diagnosis was confirmed by *V2R* mutation analysis. The proband carries a novel *AVPR2* missense mutation inherited from his carrier mother.

REFERENCES

- Aaronson IA, Wiggelinkhuizen J 1985. Nephrogenic diabetes insipidus and obstructive uropathy. *Br J Urol*, 57: 110-111.
- Anesi L, de Gemmis P, Galla D, Hladnik U 2012. Two new large deletions of the *AVPR2* gene causing nephrogenic diabetes insipidus and a review of previously published deletions. *Nephrol Dial Transplant*, 27: 3705-3712.
- Bernier V, Morello JP, Zarruk A, Debrand N, Salahpour A, Lonergan M, Arthus MF, Laperriere A, Brouard R, Bouvier M, Bichet DG 2006. Pharmacologic chaperones as a potential treatment for X-linked nephrogenic diabetes insipidus. *J Am Soc Nephrol*, 17: 232-243.
- Bichet DG, Birnbaumer M, Lonergan M, Arthus M-F, Rosenthal W, Goodyer P, Nivet H, Benoit S, Giampietro P, Simonetti S, Fish A, Whitley CB, Jaeger P, Gertner J, New M, DiBona FJ, Kaplan BS, Robertson GL, Hendy GN, Fujiwara TM, Morgan K 1994. Nature and recurrence of *AVPR2* mutations in X-linked nephrogenic diabetes insipidus. *Am J Hum Genet*, 55: 278-286.
- Birnbaumer M, Seibold A, Gilbert S, Ishido M, Barberis C, Antaramian A, Brabet P, Rosenthal W 1992. Molecular cloning of the receptor for human antidiuretic hormone. *Nature*, 357: 333-335.
- Duzenli D, Saglar E, Deniz F, Azal O, Erdem B, Mergen H 2012. Mutations in the *AVPR2*, *AVP-NP11*, and *AQP2* genes in Turkish patients with diabetes insipidus. *Endocrine*, 42: 664-669.
- Fujiwara TM, Bichet DG 2005. Molecular biology of hereditary diabetes insipidus. *J Am Soc Nephrol*, 16: 2836-2846.
- Los EL, Deen PM, Robben JH 2010. Potential of nonpeptide (ant)agonists to rescue Vasopressin V2 receptor mutants for the treatment of X-linked nephrogenic diabetes insipidus. *Journal of Neuroendocrinology*, 22: 393-399.
- Miyakoshi M, Kamoi K, Uchida S, Sasaki S 2003. A case of a novel mutant vasopressin receptor-dependent nephrogenic diabetes insipidus with bilateral non-obstructive hydronephrosis in a middle aged man: Differentiation from aquaporin-dependent nephrogenic diabetes insipidus by response of factor VII and von Willebrand factor to 1-diamino-8-arginine vasopressin administration. *Endocr J*, 50: 809-814.
- Moeller HB, Rittig S, Fenton RA 2013. Nephrogenic diabetes insipidus: Essential insights into the molecular background and potential therapies for treatment. *Endocr Rev*, 34: 278-330.
- Nakada T, Miyauchi T, Sumiya H, Shimazaki J 1990. Non-obstructive urinary tract dilatation in nephrogenic diabetes insipidus. *Int Urol Nephrol*, 22: 419-427.
- Robertson GL 2001. Antidiuretic hormone: Normal and disordered function. *Endocrinol Metab Clin North Am*, 30: 671-694.
- Satoh M, Ogikubo S, Yoshizawa-Ogasawara A 2008. Correlation between clinical phenotypes and X-inactivation patterns in six female carriers with heterozygote Vasopressin Type 2 receptor gene mutations. *Endocrine Journal*, 55: 277-284.
- Spanakis E, Milord E, Gragnoli C 1993. *AVPR2* variants and mutations in nephrogenic diabetes insipidus: Review and missense mutation significance. *J Cell Physiol*, 217: 605-617.
- Uribarri J, Kaskas M 1993. Hereditary nephrogenic diabetes insipidus and bilateral nonobstructive hydronephrosis. *Nephron*, 65: 346-349.
- van Lieburg AF, Knoers NV, Monnens LA 1999. Clinical presentation and follow-up of 30 patients with congenital nephrogenic diabetes insipidus. *J Am Soc Nephrol*, 10: 1958.
- Wesche D, Deen PM, Knoers NV 2012. Congenital nephrogenic diabetes insipidus: The current state of affairs. *Pediatr Nephrol*, 27: 2183-2204.
- Zender HO, Ruedin P, Moser F, Bolle JF, Leski M 1992. Traumatic rupture of the urinary tract in a patient presenting nephrogenic diabetes insipidus associated with hydronephrosis and chronic renal failure: Case report and review of the literature. *Clin Nephrol*, 38: 196-202.