

Antenatal Diagnosis of Partial Trisomy 8 and Partial Monosomy 1: A Case Report

Davut Güven, Kadir Bakay, Ayse Özdemir and Idris Koçak

*Department of Obstetrics and Gynecology, Faculty of Medicine, Ondokuz Mayıs University,
Samsun, Turkey*

KEYWORDS Partial Trisomy 8. Partial Monosomy 1. Echogenic Bowel. Giant Choroid Plexus Cyst

ABSTRACT A case of prenatally diagnosed partial trisomy 8 and partial monosomy 1 is described. The syndrome is associated with skeletal and cardiac anomalies, as well as hepatic calcification, presented with severe central nervous system malformations. Homogenous and complete trisomy 8 is an extremely rare case. In this case routine karyotyping with (Giemsa-Trypsin) GTG banding for diagnosis was carried out from amniotic fluid at 16 weeks of gestation. Peripheral blood of both parents were karyotyped. Only the father was found to have an abnormal karyotype; reciprocal translocation between chromosome 1p and 8p [46,XY,t(1;8)(p36.1;p21.3)]. The fetal karyotype was, [46,XY,der(1)del(1)(p36.1→pter) dup(8)(p21.3→pter)t(1;8)(p36.1;p21.3)]. This reported case of partial trisomy for this region of chromosome 8 is the first prospectively diagnosed antenatal case in which ultrasound anomalies are noted.

INTRODUCTION

Mosaicism for trisomy 8 is associated with a clinically defined syndrome of variable phenotype. These have been described in several post-natal cases and include mild to moderate neurodevelopmental delay, variable skeletal abnormalities (including some vertebral and joint anomalies), renal abnormalities and varying dysmorphic features (Berry et al. 1978; Jay et al. 1999). There have also been reports of individuals with mosaicism for a trisomy 8 cell line with normal intelligence (Jay et al. 1999; Pfeiffer et al. 1978). The variability of these phenotypic features, therefore, present a counselling dilemma when such a chromosomal complement is detected prenatally.

Mosaic trisomy 8 is a chromosome disorder defined by the presence of three copies of chromosome 8 in some cells of the body. It is characterized by distinctive facial features; mild intellectual disability; and joint, kidney, cardiac, and skeletal abnormalities. Males are more frequently affected than females. In the absence of serious problems, life expectancy is normal. Mosaic trisomy 8 is the result of a random error in the egg or sperm. Diagnosis is based on karyotype

analysis. Mosaic trisomy 8 almost always occurs in individuals without a family history of the condition (Khalifa et al. 2011).

Complete trisomy 8 is usually an early lethal condition often resulting in miscarriage during the first trimester, whereas mosaic trisomy 8 is less severe and individuals with a low proportion of affected cells may exhibit a comparatively mild range of physical abnormalities and developmental delay (Jones 2005).

Physical anomalies associated with trisomy 8 can be detected prenatally by ultrasound but it should be noted that the fetus may appear normal if it has a low proportion of aneuploid cells (Henderson and Crawford 1996; Golzio et al. 2006). Usually amniocentesis is used to confirm trisomy 8 (Hsu et al. 1997; Golzio et al. 2006). However it has been demonstrated in a mosaic case presenting with multiple malformations that karyotypes from both amniocentesis and direct chorionic villi sampling (CVS) of cytotrophoblasts can yield apparently normal results, while only the cultured CVS mesodermal core may allow the detection of trisomy 8 (Hahnemann and Vejerslev 1997; Golzio et al. 2006).

Objectives

Here in this article we aim to report a case of partial trisomy and partial monosomy for this region of chromosome 8 as the first prospectively diagnosed antenatal case in which ultrasound anomalies are noted.

Address for correspondence:

Kadir Bakay
Department of Obstetrics and Gynecology,
Faculty of Medicine,
Ondokuz Mayıs University,
Samsun, Turkey.
Mobile: 905308265858
E-mail: drkadirbakay@gmail.com

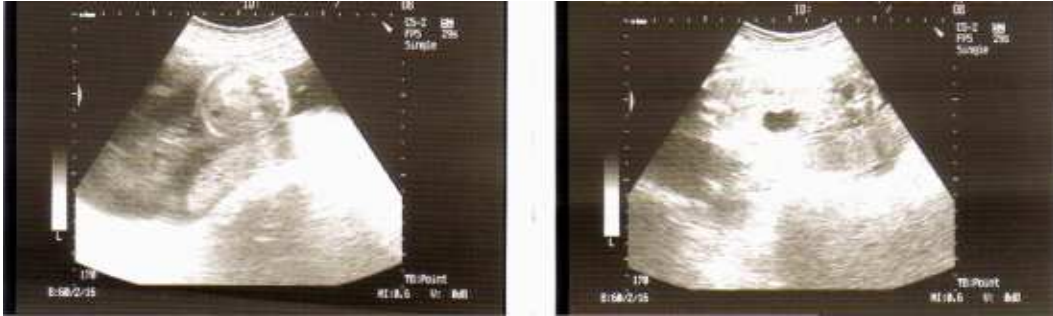


Fig. 1. Transvers and longitudinal scan of the fetus at 16 weeks gestation. Arrow points to markedly hyperechogenic areas on bowel

MATERIAL AND METHODS

Approximately 5 ml of the amniotic fluid was obtained by amniocentesis. A cytogenetic analysis of the amniotic fluid was performed to establish prenatal diagnosis. Amniotic fluid sampling was studied using classical cytogenetic technique. Cytogenetic analysis was performed on both parents using phytohemagglutinin-stimulated peripheral blood lymphocyte cultures (Moorhed et al. 1960). Metaphase chromosomes were banded by Giemsa banding (GTG) technique and 25 metaphase plaques were analyzed for each case (Seabright 1971). In cases where mosaicism was detected, metaphases up to 100 were re-analyzed. Karyotypes were described according to the International System

for Cytogenetic Nomenclature (Shaffer et al. 2009).

RESULTS

Case Report

This was the first pregnancy of a 26-year-old woman. Routine ultrasound scan at 16 weeks revealed an echogenic bowel (Fig. 1) and choroid plexus cyst (Fig. 2). There was no evidence of structural abnormality in the fetus. Direct chromosome preparations from the amniotic fluid culture showed [46,XY,der(1) del(1)(p36.1→pter) dup(8)(p21.3→pter) t(1;8)(p36.1; p21.3)] (Partial Monosomy 1p Partial Trisomy 8p) (Fig. 3).

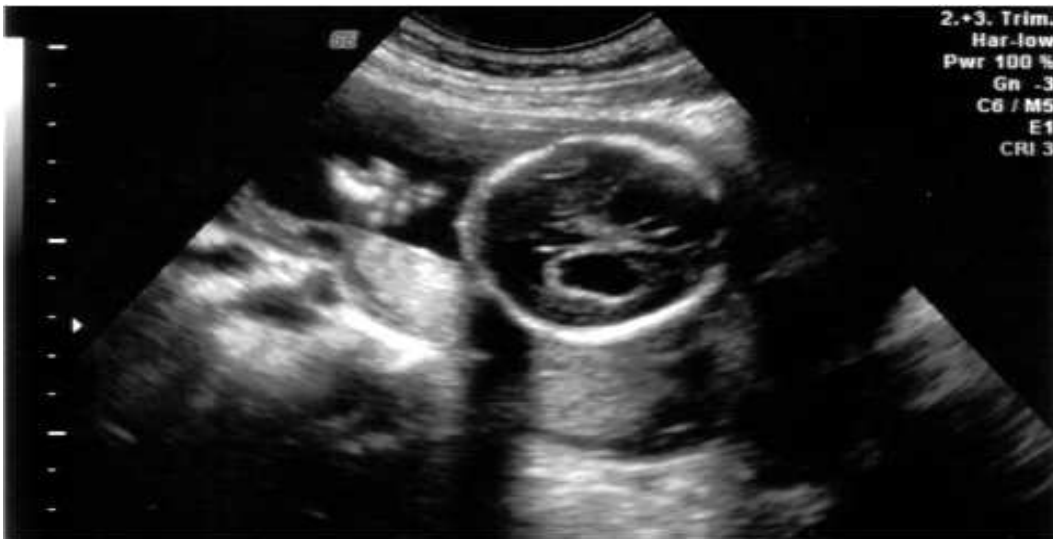
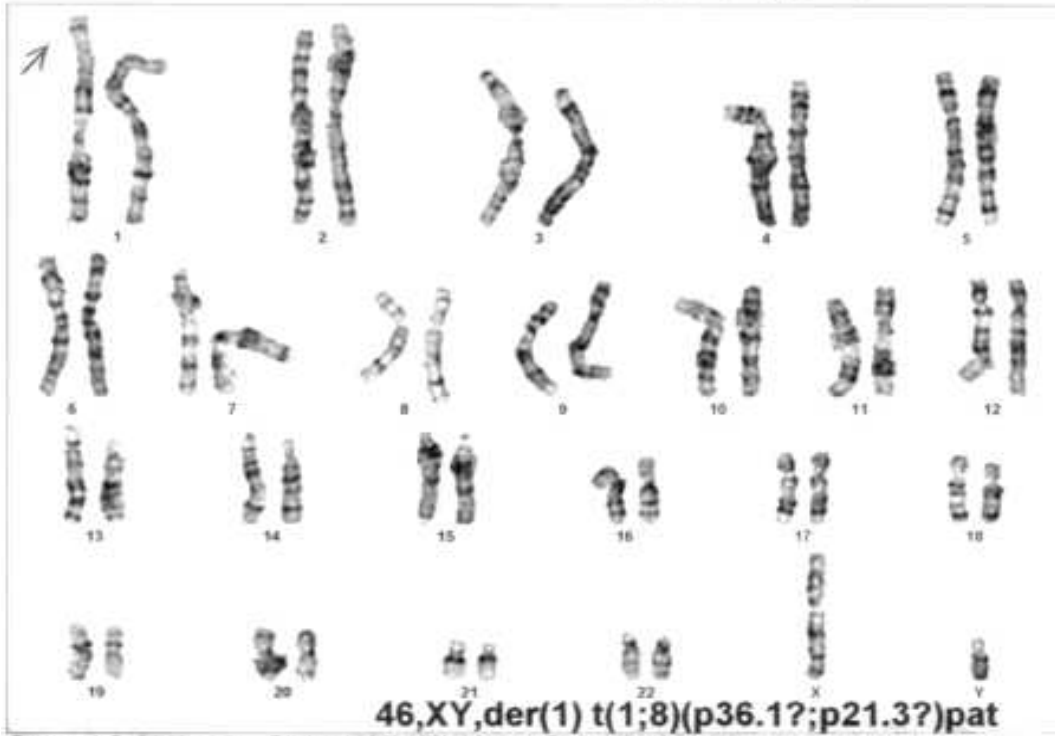
Fig. 2. Longitudinal scan of the fetus at 16 weeks gestation. Arrow points to markedly bilateral choroid plexus cyst.

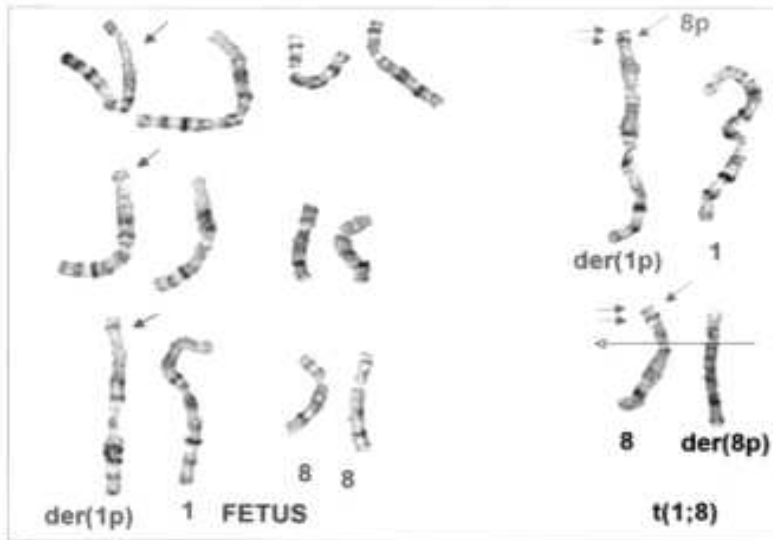
Date: 24.12.07

Specimen type: AC



Case: AC-07-0665 Slide: HAR2/FL1/L3 Cell: 12.5/154.5

Date of birth:
1981



Case: AC-07-0665 Slide: HAR1/FL2/L1 Cell: 11.0/170.4

Fig. 3. Karyotype showing partial trisomy 8

A detailed post-mortem autopsy was performed which showed a male fetus weighing 580 g with a crown-heel length of 25,9 cm, a crown-rump length of 20,3cm, a head circumference of 22,7cm and a foot length of 5.0 cm. Peripheral blood of both parents were karyotyped. Mother had normal karyotype. Father had abnormal karyotype: Reciprocal translocation between chromosome 1p and 8p [46,XY,t(1;8)(p36.1;p21.3)].

DISCUSSION

This reported case of partial trisomy for this region of chromosome 8 is the first prospectively diagnosed antenatal case in which ultrasound anomalies are noted. This case of mosaic trisomy 8 has probably been derived from a male factor post conceptional and post-fertilization chromosomal fracture error. Analysis of cultured cells showed trisomy 8 cells at all sites studied, but with much higher concentration of abnormal cells in the original biopsy (100 percent) and in two of the four sites that were analysed in follow-up (50 percent and 62 percent respectively).

Such a pattern would indicate that in this case there has been either uneven distribution of abnormal cells into the extra-embryonic mesoderm in the early pre-implantation embryo, or there has been some selection against trisomic cells in the trophoblastic derived cells (Webb et al. 1998).

Interestingly, fetal hepatic calcification has been associated with skeletal anomalies (Jay et al. 1999; Lince et al. 1985) and more recently with aneuploidy, especially in trisomies 18 and 13 (Bronshtein and Blazer 1995; Jay et al. 1999).

Parenchymal fetal calcification has not previously been reported in association with either a full or partial mosaic trisomy 8 and therefore its significance in this case is unclear. However, abnormalities of the ductus venosus are associated with hepatic calcification and an abnormality of the return of oxygenated blood might have given rise to the hepatic calcification in this case and to cardiac ischaemia and mineralization. Post-mortem did confirm some hemivertebral anomalies and a small ventricular septal defect. This was consistent with a previous postnatally-described mosaic trisomy 8 syndrome (Jay et al. 1999; Pfeiffer et al. 1978). It is also noted that

cardiac and kidney abnormalities are frequent findings in trisomy 8 syndrome (Khalifa et al. 2011). However, this is the first prenatal prospectively identified fetus with this chromosome anomaly and also the first case study where echogenic bowel has been described.

CONCLUSION

Prenatal screening should never be taken for granted and must always be performed with care and detail as shown in this case, that enabled us to antenatally diagnose the problem and made it possible to act accordingly. Otherwise a postpartum diagnosis could have a drastic effect on the parents as well as legal problems.

REFERENCES

- Berry AC, Mutton DE, Lewis DGM 1978. Mosaicism and the trisomy 8 syndrome. *Clinical Genetics*, 14: 105-114.
- Bronshtein M, Blazer S 1995. Prenatal diagnosis of liver calcification. *Obstet Gynecol*, 86: 739-743.
- Golzio Christelle, Guirchoun Jessica, Ozilou Catherine 2006. Cytogenetic and histological features of a human embryo with homogeneous chromosome 8 trisomy. *Prenatal Diagnosis*, 26-13: 1201-1205.
- Hahnemann J, Vejerslev L. 1997. Accuracy of cytogenetic findings on chorionic villus sampling (cvs)-diagnostic consequences of cvs mosaicism and non-mosaic discrepancy in centres contributing to euromic 1986-1992. *Prenatal Diagnosis*, 17: 801-820.
- Henderson N, Crawford P. 1996. The oro-facial manifestations of trisomy 8 mosaicism: a case report. *International Journal of Paediatric Dentistry*, 6: 129-132.
- Hsu L, Yu M, Neu R, et al. 1997. Rare trisomy mosaicism diagnosed in amniocytes involving an autosome other than chromosomes 13, 18, 20, and 21: Karyotype/phenotype correlations. *Prenatal Diagnosis*, 17: 201-242.
- Jay A, Kilby MD, Roberts E 1999. Prenatal diagnosis of Mosaicism for partial trisomy 8: A Case report including fetal pathology. *Prenatal Diagnosis*, 19: 976-979.
- Jones KL 2005. *Smith's Recognizable Patterns of Human Malformation*. 6th Edition. Philadelphia: W. B. Sanders Company.
- Khalifa OA, Walter CU, Rahbeeni ZA, Verloes A., 2011. Terminal 4q deletion and 8q duplication in a patient with CHARGE-like features. *Eur J Med Genet*, 54(2): 173-176.
- Lince DM, Pretorius DH, Manco-Johnson ML, Manchester D, Clewell WH 1985. The clinical significance of increased echogenicity in the fetal abdomen. *Am J Roentgenol*, 145: 683-686
- Moorhead PS, Nowell PC, Mellman WJ, Battips DM, Hungerford DA 1960. Chromosome preparation of leukocytes cultured from human peripheral blood. *Exp Cell Res*, 20: 613-616.
- Pfeiffer RA, Kassel E, Rathgen E, Kulenkampff M, Nehring T 1978. Mosaicism for an additional partial

- chromosome 8: 46,XX/47,XX,t der(8)(p21Xqter).
Human Genetics, 44: 207-212
- Seabright M 1971. A Rapid banding technique for human chromosomes. *Lancet*, 2: 971-972.
- Shaffer L.G, Slovak M.L., Campbell L.J. ISCN 2009: An International System for Human Cytogenetic Nomenclature 2009: Recommendations of the International Standing Committee on Human Cytogenetic Nomenclature, 2009; Basel: S. Karger.
- Webb AL, Wolstenholme J, Evans J, Macphail S, Goodship J 1998. Prenatal diagnosis of mosaic trisomy 8 with investigations of the extent and origin of trisomic cells. *Prenatal Diagnosis*, 18: 737-741.