

Evaluation of Cardiac Defect in a Fetus with 8p Interstitial Deletion

Angel Beula P.R.¹, Sridevi Hegde¹, Priti Venkatesh² and Jayaprakash³

¹Department of Medical Genetics, ²Department of Fetal Medicine, Manipal Hospital, Airport Road, Bangalore, 560 017, Karnataka, India

³Centre for Applied Genetics, Department of Zoology, Bangalore University, Bangalore, 560 056, Karnataka, India

KEYWORDS 8p Deletion. Prenatal Diagnosis. Congenital Heart Defects. 8p Syndrome

ABSTRACT About 30% of all malformations are of genetic origin, and congenital heart defect (CHD) is one of them. Here we report a case at 17 weeks of gestation with a small ventricular septal defect (VSD) revealed an abnormal karyotype of 46,XY,del(8)(p11.2-p21) in an amniotic fluid sample. The fetus at 21 weeks showed a progress of VSD to double outlet right ventricle, and in addition showed cleft lip, Intra Uterine Growth Retardation (IUGR) and oligohydramnios. Apart from being the first prenatal case to report a deletion spanning the region 8(p11.2-p21), this case also highlights the importance of prenatal diagnosis for cases with even a small VSD in the early scan and special attention should be paid to chromosome 8p and a proactive follow-up should be carried out to see if there is progression in the heart defect and other multiple congenital/phenotypic anomalies.

INTRODUCTION

Congenital heart defects (CHDs) are the most common cause of birth defects and are the leading cause of infant mortality (Smitha et al. 2005). CHD occurs in approximately 8 out of 1000 live births, but the rate of severe heart defects in spontaneous aborted pregnancies and still births may be 10 fold higher. The commonest heart defect is ventricular septal defect (VSD) especially due to trisomy 21.

CHDs are the single group of congenital abnormalities accounting for about 30% of the total abnormalities (Heart disease updates 2003). (www.americanheartassociation.com). There is increasing evidence that genetic factors play a major role in the pathogenesis of specific types of congenital heart defects (Payne 1995; Burn 1998). The heart defects are thought to result from an abnormal dosage of one or more gene(s) within these chromosomal fragments. At present, very few genes for CHD have been identified; much interest is paid to the association between certain chromosomal aberrations and a specific

type of CHD. Examples include deletions in chromosome 22q11.2 and conotruncal heart malformations (Wilson et al. 1993), as well as trisomy 21 and atrioventricular septal defect (AVSD) (Korenberg et al. 1992).

The genetic defects in the contiguous region of 8p is similar to the other well known contiguous gene syndromes such as: Langer-Giedion del(18q24.1), DiGeorge/Velo-cardiofacial del(22q11.2), Williams del(17q11.23) and Smith-Magenis del(17p11.2) (Dallapiccola 1995; Ligon 1997). It has been recognized that, deletions in the distal region of chromosome 8p (del8p) are associated with CHD, typically in the form of AVSD (Marino 1992; Digilio 1998). Besides a CHD, frequent phenotypic manifestations of del8p include intrauterine growth retardation, microcephaly, and mild mental retardation (MR) (Dobyns et al. 1985; Hutchinson et al. 1992).

We report a case of 17 weeks fetus with a small ventricular septal defect (VSD) of 46,XY,del(8)(p11.2-p21) karyotype, which at 21 weeks showed progression of ventricular septal defect (VSD) to double outlet right ventricle and addition of cleft lip, Intra Uterine Growth Retardation (IUGR), and oligohydramnios.

MATERIALS AND METHODS

After obtaining written consent from the expected mother/couple, a detailed study was done, which included the recording of patient's history,

Address of correspondence:

Angel Beula.P.R.

c/o Dr. Jayaprakash

Centre for Applied Genetics, Department of Zoology,

Bangalore University, Bangalore, 560 056,

Karnataka, India

Telephone: +91-080-9449617767

E-mail: angel_bpr@yahoo.co.in

detailed pedigree analysis in the pre-designed sheets, followed by the sample collection, inoculation and cytogenetic study. For this case about 20ml of amniotic fluid was collected from pregnant mother at 17 weeks of gestation in a sterile condition, and the sample was spun at 800 rpm for 10 min to get the cell pellet. The culture was set up in 2 sterile flasks with the different combination of amniomax C-100 Basal medium (GIBCO BRL) and F-10 Nutrient medium (HAM)- (GIBCO BRL). The flasks were incubated at 37°C and regularly checked for the colonies and media changes were given. When sufficient colonies with doublets were seen, the cells were harvested and slides were prepared and GTG banded for chromosomal study.

A subsequent scan of the fetus was done at 21 weeks to confirm the clinical correlation of 8p deletion, and cord blood culture was set up in the RPMI-1640 media (Rosewell Park Memorial Ins) (GIBCO BRL) containing Phytohemagglutinin M (PHA). After 72 hrs of incubation at 37°C, cells were harvested and slides were prepared and GTG banded with Giemsa stain for the analysis of chromosomes.

CASE REPORT

A 26 years old mother, consanguineously married was referred for prenatal diagnosis (PND) at 17 weeks gestation. Her first 11 years old male child was normal and the second four years old male child had Down syndrome. An ultrasound scan was performed on the fetus at 17 weeks and it revealed a small ventricular septal defect. Following the sonographic examination, an amniocentesis was performed because of suspected cardiac defects and the previous history of Down syndrome. Prenatal cytogenetic analysis was performed with the amniotic fluid using an *in situ* culture method and standard G-banding techniques. The karyotype in the fetus showed 46XY,del(8)(p11.2-p21) in all 20 metaphases analysed. A chromosomal investigation of the parents and the first sibling using peripheral blood samples revealed a normal karyotype. Based on the results of fetal chromosomal analysis, the couple were advised for a scan and at 21 weeks. Subsequently the fetus was scanned at 21 weeks to confirm the clinical correlation of 8p deletion which showed a progress of VSD to double outlet right ventricle along with IUGR, oligohydramnios and cleft lip and palate. The

karyotype obtained by GTG banding of the fetal cord blood was confirmed as 46,XY,del(8)(p11.2-p21). Based on the results of fetal chromosomal analysis of both amniotic fluid and cord blood, genetic counselling was provided and the couple who opted for medical termination of the pregnancy. The post-mortem examination of the fetus confirmed the ultra sound findings. On dissection of the heart, it confirmed the cardiac defect.

RESULTS

The cytogenetic studies on amniotic fluid sample at 17 weeks of gestation, revealed a karyotype of 46XY, del(8)(p11.2-p21) (Fig. 1). To know the origin of the deleted chromosome, a cytogenetic investigation of the parents was carried out using peripheral blood sample. It revealed a normal karyotype for both, indicating that, 8p interstitial deletion was of *de novo* origin. Subsequent scan of the fetus at 21 weeks and the chromosomal analysis of the cord blood showed the same deletion at 8p region. The post mortem examination of the abortus confirmed the ultra sound findings.

DISCUSSION

The interesting finding of this case was of 8p interstitial deletion (p11.2-p21) which highlights the importance of PND for fetuses with cardiac defects. Reports on 8p syndrome include deletion of chromosome 8p at various loci with varying phenotypical abnormalities. Distal 8p deletion (8p23.1-8pter) - major congenital anomalies (Hutchinson et al. 1992), del 8 (p23.1-p 23.1) - Diaphragmatic hernia (Shimokawa et al. 2005), del8 (p23.1) - heart abnormalities (Pehlivan et al. 1999), and del 8(p21.3-pter) - fetus with growth retardation, imbalance atrioventricular septal defect (AVSD) and hypoplastic right ventricle (Devriendt et al. 1998).

Deletion of a 5cM region at chromosome 8p 23 is associated with a spectrum of congenital heart defects (Gigglio et al. 1999) including conotruncal lesion, atrial septal defects, atrioventricular canal defects and pulmonary valve stenosis. GATA 4 zinc finger transcription factor at 8p22-23 mutations is also reported in septal heart defects (Garg et al. 2003).

Atrio-ventricular canal, hypoplastic right ventricle and pulmonary atresia are consistent with published reports of deletion from 8p21-pter.

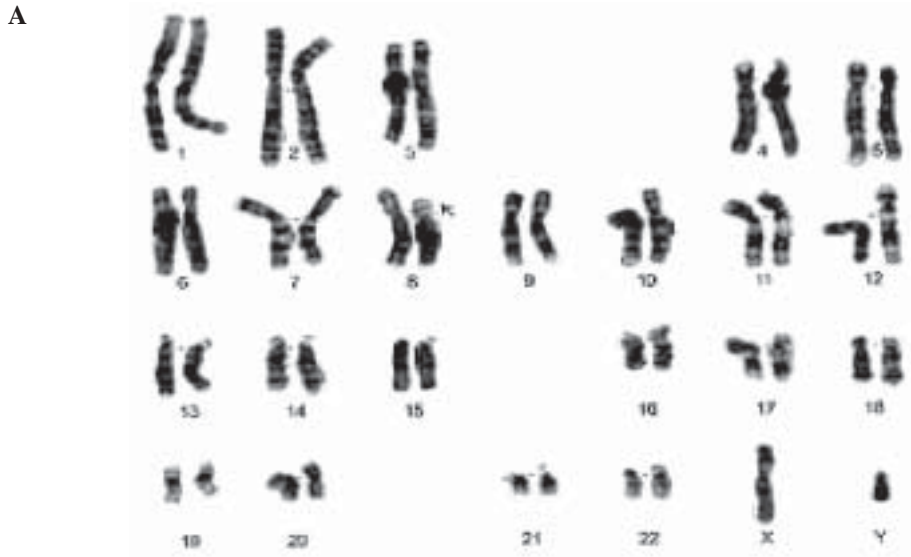


Fig. 1a. Karyotype showing 46,XYdel(8)(p11.2-p21)

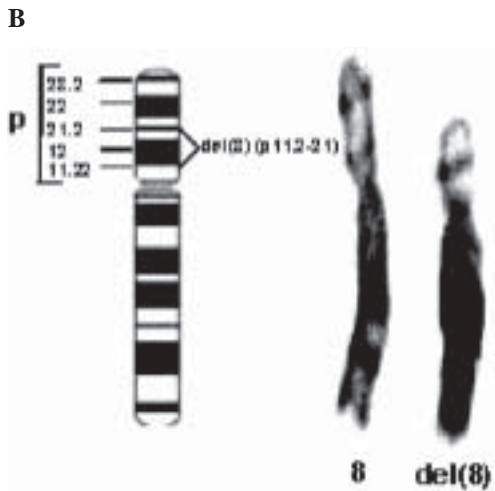


Fig. 1b. Partial karyotype showing the normal and deleted chromosomes after GTG banding

While some reports describe instead an atrio-ventricular septal defect with or without pulmonary atresia, all previous studies report defects in cardiac chamber formation (Digilio et al. 1993, 1998). Mapping of cardiac abnormalities to very small region 8p23.1-pter suggests that the region of 8p23.1 harbours an important gene for the development of the heart (Sangeeta et al. 1999).

Table 1: Comparison between the previous reported case and the present case

Two cases (Post-natal)	Present case (Pre-natal 21 weeks)
1. del 8p (p11.21-p11.23)	del 8p(p11.2-p21)
2. del 8p (p11.23-p21.3)	
a. Congenital heart defect	CHD-VSD and double outlet right ventricle
b. Low birth weight	Symmetrical IUGR
c. Thin lip and high arched palate	Small cleft lip and palate
c. Mental retardation	Oligohydramnios
d. Dolichocephaly.	
(Tsukahara et al. 1995).	

The most common characteristics of interstitial deletions of proximal 8p(p12-p21) are developmental delay, postnatal microcephaly and growth retardation (Willemsen et al. 2009). Delayed mental and motor development, ophthalmological abnormalities, and peripheral neuropathy were reported in a girl with break-points located on 8p (p12-p21.2) (Klopocki et al. 2006).

CONCLUSION

The literature review suggested that deletions of the terminal short arm of chromosome 8 are rare, and most of them demonstrate a common break point at 8p23 region (Bosse et al. 2004) that is the region 8p(p22-p23.1) which contains GATA 4 gene causing congenital heart defects. Reports

suggest that the del8p phenotype often is relatively mild, without associated facial dysmorphism or major internal malformations (Fryns et al. 1989, Hutchinson 1992; Wu et al. 1996). However deletion spanning 8(p11.2-p21) can also give rise to congenital heart defects like ventricular septal defect, atrio-ventricular septal defect and other phenotypic abnormalities like cleft lip and microcephaly as illustrated by our case and other two postnatal reports, with a slightly different break point that is at 8(p11.21-p11.23) and 8(p11.23-p21.3).

This would be the first prenatal case to report a deletion spanning 8(p11.2-p21) which is quite a large region. Although not involving 8p23 GAT A4 region, this region can also give rise to congenital heart defects like VSD, AVSD and phenotypic abnormalities like cleft lip and microcephaly. This suggests that, patients with CHD but without a deletion in 22q11 or without a trisomy 21, attention should be focused on 8p deletion. It also highlights the importance of PND for cases with even a small VSD seen in the early scan, should be suggested a proactive follow-up to see if there is progression in the heart defect and other multiple congenital/phenotypic anomalies.

REFERENCES

- Devriendt K, De Mars K, De Cock P, Gewillig M, Fryns JP 1995. Terminal deletion in chromosome region 8p23.1-8pter in a child with features of velo-cardio-facial syndrome. *Ann Genet*, 38: 228-230.
- Devriendt K, Matthijs G, Van Dael R, Gewillig M, Eyskens B, Hjalgrim H, Dolmer B, McGaughran J, Brondum-Nielsen K, Marynen P, Fryns JP, Vermeesch JR 1999. Delineation of the critical deletion region for congenital heart defects, on chromosome 8p23.1. *Am J Hum Genet*, 64: 1119-1126.
- Devriendt K, Van Schoubroeck D, Eyskens B, Gewillig M, Vandenberghe K, Fryns JP 1998. Prenatal diagnosis of terminal short arm deletion of chromosome 8 in a fetus with an atrio-ventricular septal defect. *Prenat Diagn*, 18: 65-67.
- Digilio MC, Marino B, Guccione P, Giannotti A, Mingarelli R, Dallapiccola B 1998. Deletion 8p syndrome. *Am J Med Genet*, 75: 534-536.
- Dobyns W.S, Dewald G.W, Carlson R.O, Mari D.D, Michels V.V 1985. Deficiency of chromosome 8p21.1-8pter: case report and review of the literature. *Am J Med Genet*, 22: 125-134.
- Fryns J.P, Kleczkowska A, Vogels A, Van Den Berghe H 1989. Normal phenotype and slight mental retardation in *de novo* distal 8p deletion (8pter.....8p23.1). *Ann Genet*, 32: 171-173.
- Garg V, Kathiriyia IS, Barnes R, Schluterman M.K, King IN, Butler CA, et al. 2003. GATA4 mutations cause human congenital heart defects and reveal an interaction with TBX5. *Nature*, 424: 443-447
- Hutchinson R, Wilson M, Voullaire L 1992. Distal 8p deletion (8p23.1-8pter): A common deletion ? *J Med Genet*, 29: 407-411.
- Klopocki E, Fiebig B, Robinson P, Tonnies H, Erdogan F, Ropers HH, Mundlos S, Ullmann R 2006. A novel 8 Mb interstitial deletion of chromosome 8p12-p21.2. *Am J Med Genet*, A, 15: 140, 873 -877.
- Marion B, Reale A, Gionnotti A, Digilio MC, Dallapiccola B 1992. Nonrandom association of atrioventricular canal and del(8p) syndrome. *Am J Med Genet*, 42: 424-427.
- McElhinney DB, Geiger E, Blinder J, Benson W, Goldmuntz E 2003. NKX2.5 Mutations in patients with congenital heart disease. *J Am Coll Cardiol*, 24: 448-453.
- Meberg A, Otterstad J.E, Froland G, Sorland S, Nitter Hauge S 1994 Increasing incidence of ventricular septal defects caused by improved detection rate. *Acta Paediatr*, 83: 653-657.
- Ostergaard GZ, Tommerup N 1989. The 8p- syndrome. *Ann Genet*, 32 : 87-91
- Patil SR, Hanson J.W 1980. Partial 8p-syndrome. *J Genet Hum*, 28: 123-129.
- Pecile V, Petroni M.G, Fertz MC, Filippi G 1990. Deficiency of distal 8p - report of two cases and review of the literature. *Clin Genet*, 37: 271-278.
- Pehlivan T, Pober B.R, Brueckner M, Garrett S, Slauch R, Van Rheaden R, Wilson DB, Watson MS, Hing AV 1999. GATA4 haploinsufficiency in patients with interstitial deletion of chromosome region 8p23.1 and congenital heart disease. *Am J Med Genet*, 83: 201-206.
- Reiss JA, Brenes PM, Chamberlin J, Magenis RE, Lovrien EW 1979. The 8p-syndrome. *Hum Genet*, 47: 135-140.
- Sangeeta NB, Veena S, Albert B, Celeste M, Krauss 1999. Prenatal Detection and Mapping of a Distal 8p Deletion Associated with Congenital Heart Disease. *Prenat Diagn*, 19: 863-867.
- Shimokawa O, Miyake N, Yoshimura T, Sosonkina N, Harada N, Mizuguchi T, Kondoh S, Kishino T, Ohta T, Remco V, Takashima T, Kinoshita A, Yoshiura K, Niikawa N, Matsumoto N 2005. Molecular characterization of del(8)(p23.1p23.1) in case of congenital diaphragmatic hernia. *Am J Med Genet A*, 1; 136(1): 49-51.
- Smitha Ramegowda, Nallur B. Ramachandra 2005. An understanding the genetic basis of congenital heart disease. *Indian Journal of Human Genetics*, 11: 14-23.
- Tsukahara M, Murano I, Aoki Y, Kajii T, and Furukawa.S 1995. Interstitial deletion of 8p: report of two patients review of the literature. *Clin Genet*, 48: 41-45.
- Willemsen MH, de Leeuw N, Pfundt R, de Vries BB, Kleefstra T 2009. Clinical and molecular characterization of two patients with a 6.75 Mb overlapping deletion in 8p12p21 with two candidate loci for congenital heart defects. *Eur J Med Genet*, 52: 134-139
- Wu BL, Schneider GH, Sabatino DE, Bozovic LZ, Cao B, Korf BR 1996. Distal 8p deletion (8)(p23.1): an easily missed chromosomal abnormality that may be associated with congenital heart defect and mental retardation. *Am J Med Genet*, 62: 77-83.