

Chromosomal Anomalies and Congenital Heart Disease in Mysore, South India

Smitha Rame Gowda¹, Harshavardhan M. Gawde², Abbas Hyderi³, Mysore R. Savitha³,
Balasundaram Krishnamurthy³, Sameul C. Karat⁴, Narayanappa Doddaiiah⁵, Zareen M. Patel² and
Nallur B Ramachandra^{1*}

¹Human Genetics Laboratory, Department of Studies in Zoology, University of Mysore,
Manasagangothri, Mysore 570 006, Karnataka, India

²National Institute for Research In Reproductive Health, Genetic Research Center
(GRC)-ICMR, J. M. Street, Parel, Mumbai 400 012, Maharashtra, India

³Department of Pediatrics, Cheluvamba Hospital, Mysore, Karnataka, India

⁴Department of Pediatrics, CSI Holdsworth Memorial Hospital, Karnataka, India

⁵Department of Pediatrics, JSS Hospital, Mysore, Karnataka, India

KEYWORDS Birth Defects. Congenital Heart Disease. Syndromes. Numerical and Structural Chromosomal Anomalies

ABSTRACT Congenital heart disease (CHD) is the most common form of human birth defects accounting for about 30% of the total anomalies. The prevalence of CHD worldwide is found to range between 1.0 – 150/ 1000 live births. The causes for CHD can be categorized into three major groups such as, chromosomal (0.4 - 26.8%), single gene disorders (10-15%) and multiple factors (85-90%). Here we report the association of chromosomal variations with CHD in Mysore. A total of 192 confirmed CHD cases were considered for the present study whose age ranged from 1 day to 23 years. After written consent was obtained from the family members, 136 CHD patients were subjected for conventional cytogenetic studies and some of them for FISH analysis. Of these, 18 patients were with numerical abnormalities, 3 patients with structural abnormalities, one patient with both numerical and structural abnormalities and remaining 114 patients with normal chromosomes. Thus, the present findings are the maiden report from Mysore, which have contributed richly towards the association of chromosomal anomalies with CHD and pointing out chromosome 9 a possible killer chromosome for the cause of CHD.

INTRODUCTION

Congenital heart disease (CHD) is the most common form of human birth defects accounting for about 30% of the total anomalies (<http://www.fi.edu/biosci/develop/develop.html>), which is found to affect nearly 1% of newborns, and their frequency in spontaneously aborted pregnancies is estimated to be tenfold higher (Behrman et al. 2000). Population based studies on the prevalence of CHD worldwide is found to range between 1.0 – 150 per 1000 livebirths (Smitha et al. 2006b), whereas, in India it is found to range from 2.2 to 50.89 per 1000 livebirths (Tank et al. 2004; Smitha et al. 2006b). The causes for CHD can be categorized into three major groups

such as, chromosomal, single gene disorders (10-15%) and multiple factors (85-90%) (Payne et al. 1995). The refinements in cytogenetic techniques have promoted progress in understanding the role played by chromosomal anomalies in the cause of CHD (Noonan 1978). It is found that about 0.4 - 26.8% of all CHD are associated with several chromosomal anomalies like numerical and structural variations (Naganuma et al. 1981; Ferencz et al. 1989; Roskes et al. 1990; Allan et al. 1991; Grech and Gatt 1999; Knight et al. 1999; Prasad and Chudley 2002; Patel et al. 2004; Ergun et al. 2004; Riegel et al. 2005; Soares et al. 2005). The present investigation is first of its kind from Mysore, South India in which an attempt had been made to systematically study the association of chromosomal variations with CHD in Mysore. The investigation was carried out from the year September 2003 - August 2005 in three major hospitals, K. R. Hospital, CSI Holdsworth Memorial Hospital and J.S.S Hospital, Mysore. The subjects of the study included pediatric livebirths and inpatients who had been examined for various illness in the hospitals by the pedia-

*For correspondence:

Dr. N. B. Ramachandra
Human Genetics Laboratory
Department of Studies in Zoology
University of Mysore, Manasagangothri
Mysore 570 006, Karnataka, India
Phone: 0821-2516056; Mobile: 9880033687
E-mail: nallurbr@gmail.com

tricians. The suspected CHD patients or strong familial cases had been subjected by the pediatricians for further clinical diagnosis, extensive X-ray analysis, electrocardiogram and echocardiography examination for confirmation of the defect/disease.

A total of 192 confirmed CHD cases were considered for the present study whose age ranged from 1 day to 23 years. After written consent was obtained from the family members, 136 CHD patients were subjected for conventional cytogenetic studies, which were carried out on peripheral blood lymphocyte culture using standard protocol with little modifications. G-banded metaphases were screened using Leica DMRA2 research microscope. A total of 50 well-banded metaphase plates were analyzed and karyotyped according to the International System for Human Cytogenetic Nomenclature (ISCN 2005). Further Florescence in situ hybridization (FISH) analysis was carried out on interesting CHD patients using telomeric, centromeric [Vysis Inc, France] and multicolor-FISH probes [METASYSTEMS, Germany] on peripheral blood samples as per the protocols supplied by the manufacturer, and with suitable modifications.

By using cytogenetic and FISH technique, about 16% of common, rare and unique numerical and structural chromosomal anomalies associated with CHD were observed. The patients with numerical abnormalities were grouped into syndromic CHD, as they were associated with extracardiac features and the patients with no extracardiac features were grouped into nonsyndromic CHD. Of the 136 CHD patients, 117 were isolated CHD, while 19 patients were syndromic CHD. Of these, 18 patients were with numerical abnormalities, 3 patients with structural abnormalities, one patient with both numerical and structural abnormalities and remaining 114

Table 1: Number of congenital heart disease patients with chromosomal anomalies.

No. of CHD	Chromosomal anomalies
114	Nil
17	Free Trisomy 21
01	Isochromosome 18p
01	Free Trisomy 21 with reciprocal translocation between subtelomeric regions of chromosomes 9q and 13q
02	Pericentric inversion in chromosome 9
01	Complex variant translocation between chromosomes 5q, 9p, 11p and 13q
136	16.18%

patients with normal chromosomal complement (Table 1).

Syndromic CHD and Chromosomal Anomalies

One of the most commonly associated syndromes with CHD is Down syndrome (DS), which is found in 0.6% of the general population (Malini and Ramachandra 2006). About 40 - 60% of trisomy 21 patients have CHD with varying degree of clinical features (Stoll et al. 1998), with cardiac malformations as the principal cause of mortality in the first two years of life (Tubman et al. 1991). In the present study, among the numerical chromosomal abnormalities, free Trisomy 21 was found in 17 CHD patients. Table 2 provides the standard characteristic clinical features of DS, which were present in 17 cases of free trisomy 21. There are reports that all characteristic craniofacial and physical features of DS are not present in every case (Kava et al. 2004). Similarly, all the 17 trisomy 21 patients analyzed have shown only few of the characteristic clinical features consistent with the reported cases of DS with free trisomy 21, identified cytogenetically. The common clinical features found in these patients

Table 2: Characteristic clinical features of congenital heart disease patients with free Trisomy 21.

S. No.	Standard characteristic features	Clinical features observed	
		No.	Expression in %
1	Mongoloid slant	17	10.00
2	Delayed development	2	11.76
3	Simian crease	3	17.65
4	Epicanthal folds	8	47.06
5	Hypertelorism	0	0
6	Microcephaly	6	35.29
7	Flat nasal bridge	17	100
8	Hypotonia	1	5.88
9	Sandal gap sign	4	23.53
10	Ear abnormalities	0	0
11	Brachycephaly	0	0
12	Congenital heart diseases	17	100
13	Congenital cataracts	0	0
14	Clinodactyly	0	0
15	Brachydactyly	0	0
16	Short stature	4	23.53
17	Hypothyroidism	0	0
18	Strabismus	0	0
19	Nystagmus	0	0
20	Brushfield spots	0	0
21	Imperforate anus	0	0
22	Tracheoesophageal fistula	0	0
23	Hirschsprung disease	0	0
24	Duodenal atresia	0	0

were CHD, mongoloid slant and flat nasal bridge. The most common CHD associated with DS worldwide is found to be Atrioventricular canal defect (AVSD), followed by Ventricular septal defect (VSD), Atrial septal defect (ASD), Coarctation of Aorta (COA), Tetralogy of Fallot (TOF), Patent ductus arteriosus (PDA) etc. (Ferencz et al. 1989; Grech et al. 1999; Paladini et al. 2000; Ahmed et al. 2005). In India, the common CHD found to be associated with trisomy 21 are VSD followed by ASD, PDA and TOF (Kava et al. 2004). Similarly, in the present investigation, the most common cardiac defect found in these trisomy 21 patients was VSD (58.82%), followed by Complex CHD (23.53%), ASD (11.76%) and AVSD (5.88%) (Fig.1). Advanced maternal or paternal age has been noted for long time in a series of families with the proband having trisomy 21 (Fisch et al. 2003; Kothare et al. 2002). However, in the present investigation, it was seen that none of parent's age of trisomy 21 patients was advanced, which rules out the advanced age as a risk factor for the occurrence of trisomy 21 in the probands affected with CHD.

Trisomy 21 patients are also found to be associated with a small degree of translocations involving the acrocentric chromosomes. Literature reveals that about 2 - 3% of the DS patients have translocations like the robertsonian translocation, which involves the whole arm exchange between acrocentric chromosomes 13, 14, 15, 21, and 22 (Bandyopadhyay et al. 2003). In our investigation, one of the probands had trisomy 21, with a novel reciprocal translocation between the subtelomeric regions of chromosome 9q and 13q [47,XY,+21,t(9;13)(q34.1;q34)] by FISH analysis.

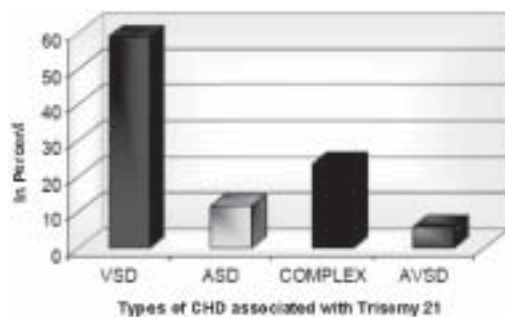


Fig. 1. Different types of congenital heart disease associated with Trisomy 21.

The male proband was the second-born child of nonconsanguineous young parents. Clinical investigations revealed low set ears, flat occiput, depressed nasal bridge, mongoloid slant, clinodactyly, two phalanges in fingers, simian crease and CHD. These clinical features further lead to the suspicion of the presence of trisomy 21 in the proband. Echocardiographic examination confirmed the CHD as nonrestrictive ostium secundum (OS) type of ASD (9mm). Analysis of 50 G-banded metaphases revealed trisomy 21 confirming the clinical diagnosis along with a subtelomeric deletion on chromosome 9 [47,XY,+21,del 9(q34.1)] (Fig. 2). FISH analysis confirmed the presence of trisomy 21 in all the 50 metaphases screened using a mixture of LSI and centromeric probes (chromosome 13, 18 and 21) thus, confirming the case to be nonmosaic. Further, FISH analysis was carried out in order to confirm the subtelomeric deletion, but instead a reciprocal translocation between the subtelomeric regions of chromosome 9q and 13q [t (9;13)(q34.1;q34)] (Fig. 3) was found in all the 50 metaphases analyzed (Unpublished data). One of the limitations faced in this case was the non-cooperation by the parents to take part in the cytogenetic investigation. This is a maiden novel finding in a patient with CHD and trisomy 21.

In another female dysmorphic child we found a *de novo* i(18p), (Smitha et al. 2006a) confirmed by cytogenetic and FISH analysis [47,XX + i(18p)]. It is a rare chromosomal abnormality, occurring once in every 140,000 livebirths, affecting males and females equally. Most of the i(18p) cases reported so far in the literature are sporadic due to *de novo* formation, while familial and mosaic cases are infrequent. However, the present case, could be due to the somewhat advanced maternal age (32 years) and/or expression of recessive genes in the proband, who is the progeny of consanguineous marriage, which could have led to misdivision and nondisjunction of chromosome 18 in meiosis I, followed by failure in the chromatid separation of 18p in meiosis II and by inverted duplication.

Nonsyndromic CHD and Chromosomal Anomalies

Structural chromosomal anomalies such as translocations (reciprocal translocations, subtelomeric translocations etc.), duplications, inversions and microdeletions have been

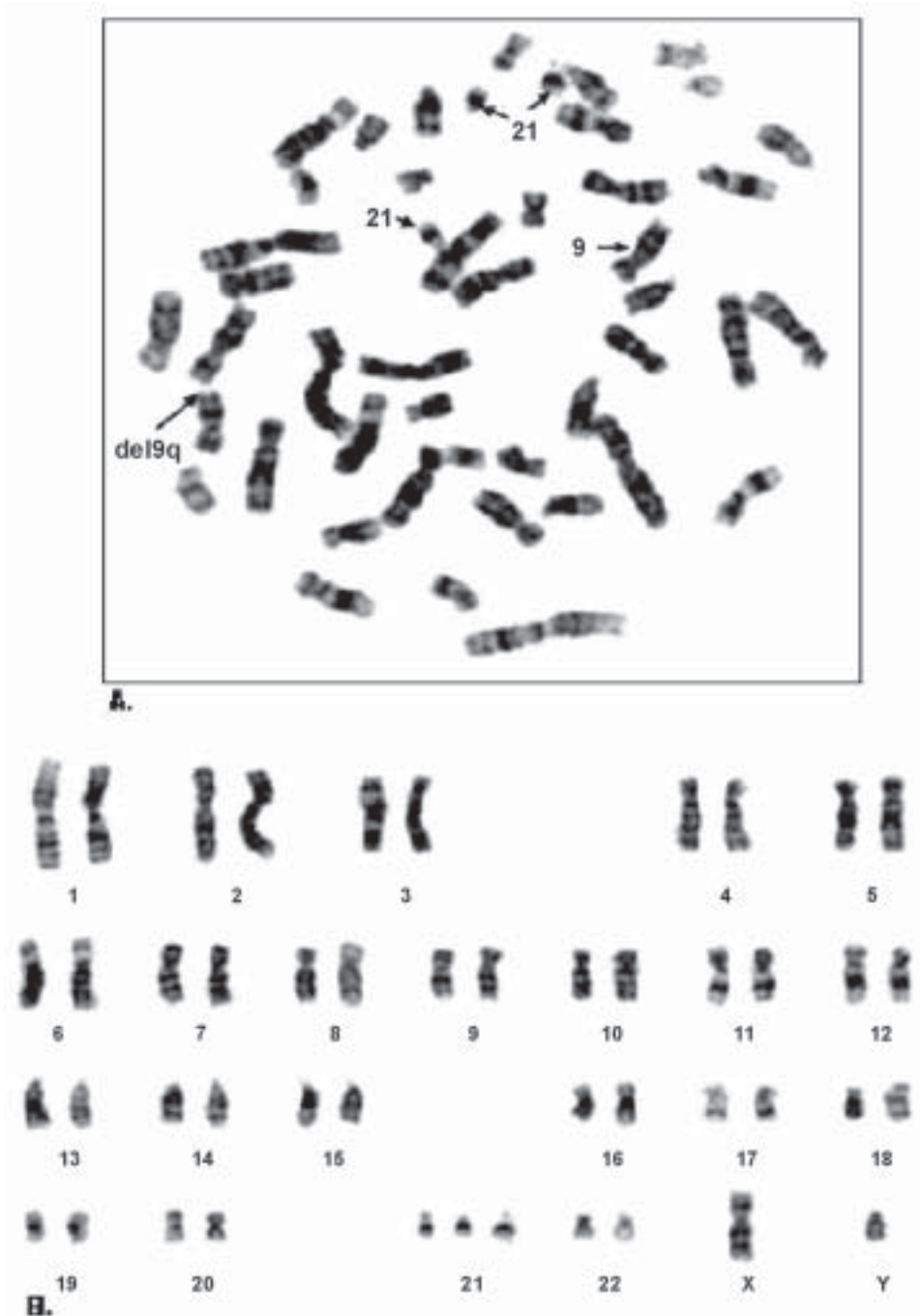


Fig. 2. G-banded metaphase chromosomes of the congenital heart disease patient with trisomy 21 and subtelomeric deletion on chromosome 9 [47,XY, +21, del 9 (q34.1)]: (A) Metaphase showing (i) Trisomy 21 (arrow); (ii) subtelomeric deletion (arrow) and (B) karyotype of the metaphase.

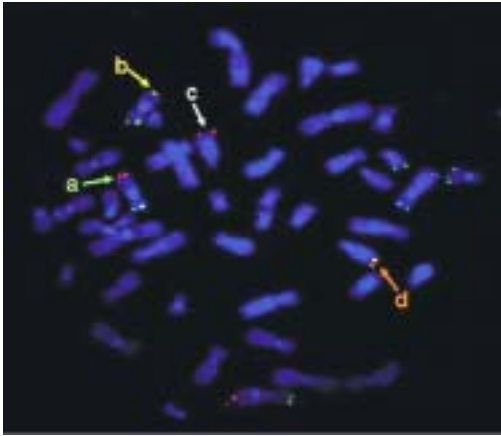


Fig. 3. FISH image showing the reciprocal translocation between subtelomeric region of chromosome 9q and 13q on metaphase chromosomes of the proband [47,XY,+21,t(9;13) (q34.1;q34)]: (a) Normal chromosome 9q region (Spectrum red); (b) Chromosome 9 with sub-telomeric region of chromosomes 13 (spectrum green and spectrum orange); (c) Chromosome 13q with subtelomeric region of chromosome 9 (Spectrum red) and (d) Normal chromosome 13q region (Spectrum green and spectrum orange).

reported in association with nonsyndromic CHD (Back et al. 1994; Smith et al. 1994; Baruch and Erikson 2001; De Vries et al. 2003, Neas et al. 2005; Riegel et al. 2005). Cytogenetic aberrations like aneuploidy, deletions, translocations and inversions on chromosome 9 have been reported to be one of the most frequent abnormalities. The range of phenotypic consequences found to be associated with these abnormalities are mild growth retardation, malformations of the skull and facial (craniofacial) region, abnormalities of the hands and fingers, skeletal malformations, and/or cardiac defects (Boby et al. 1994; Mokhtar 1997; McAuliffe et al. 2005). Among these anomalies pericentric inversion of chromosome 9 is one of the most common balanced structural chromosomal aberrations found in 1 to 3% of the general population (Nielson and Silesen 1975; Ko et al. 1992; Teo et al. 1995; Humphray et al. 2004). There are several conflicting reports on the association of this inversions with subfertility, sterility, recurrent miscarriage, schizophrenia, congenital myotonic dystrophy, cerebral cyst, dysmorphic signs, mental retardation, psychiatric disorders and other abnormal clinical conditions (Krishna et al. 1992; Scarinci

et al. 1992; Teo et al. 1995; Gardner and Sultherland 1996; Kunugi et al. 1999; Davalos et al. 2000; Parmar and Sira 2003; Srebniak et al. 2004).

In the present investigation, we found two different cases of pericentric inversion of chromosome 9 [inv(9)(p11-q13)], associated with Total Anomalous Pulmonary Venous Connection (TAPVC) and Tetralogy of Fallot (TOF). In one of the cases (TOF), the mother had similar chromosome 9 inversion without CHD. We predicted that, the genes responsible for the normal heart development could be present on chromosome 9 around p11-q13 region, which might have been defective during the process of inversion and thereby resulted in CHD. To our knowledge, this is the maiden report of association of chromosome 9q inversion with CHD from South India (Smitha et al. 2007).

In another proband, we found a novel complex variant translocation involving chromosome 5q, 9p, 11p and subtelomeric region of 13q. The proband was the first liveborn child of non-consanguineous parents. Clinical investigations revealed that the proband was suffering from CHD. Echocardiographic investigation confirmed the presence of a complex CHD which included a small sized muscular VSD (3mm), nonrestrictive ASD with OS type (7mm) and a large side PDA (6mm). Ophthalmologist investigation revealed that the child was suffering from anoxia amblyopia and audiological investigation suspected deafness. A follow-up study was carried on the proband at 5 months of age. A repeat echocardiographic examination at 5 months revealed the presence of a large size PDA (6mm) with a small sized muscular VSD (3mm). Pedigree analysis of the probands family revealed that there was no history of birth defects or genetic defects in the family.

Cytogenetic analysis (G-banding) of the proband revealed normal diploid chromosome complement with a possible reciprocal translocation involving chromosomes 5 and 9 in all the 50 metaphases screened (Fig. 4). Chromosomal investigations in both the parents revealed normal karyotypes indicating the case to be a *de novo*. In order to confirm the reciprocal translocation, M-FISH analysis was carried out. The analysis of metaphases confirmed involvement of chromosome 5 and 9, but also revealed the involvement of chromosome 11 and 13 in the complex variant translocation i.e. t(5;9;11;13) (q14;p24;p15;q33) (Fig. 5, Unpubli-shed data).




Fig. 4. G-banded chromosomes of the congenital heart disease patient with a possible reciprocal translocation between chromosomes 5 and 9 [t(5;9)(q14;q34)]: (A) Metaphase showing t(5;9)(q14;p24), and (B) Karyotype of the above metaphase.

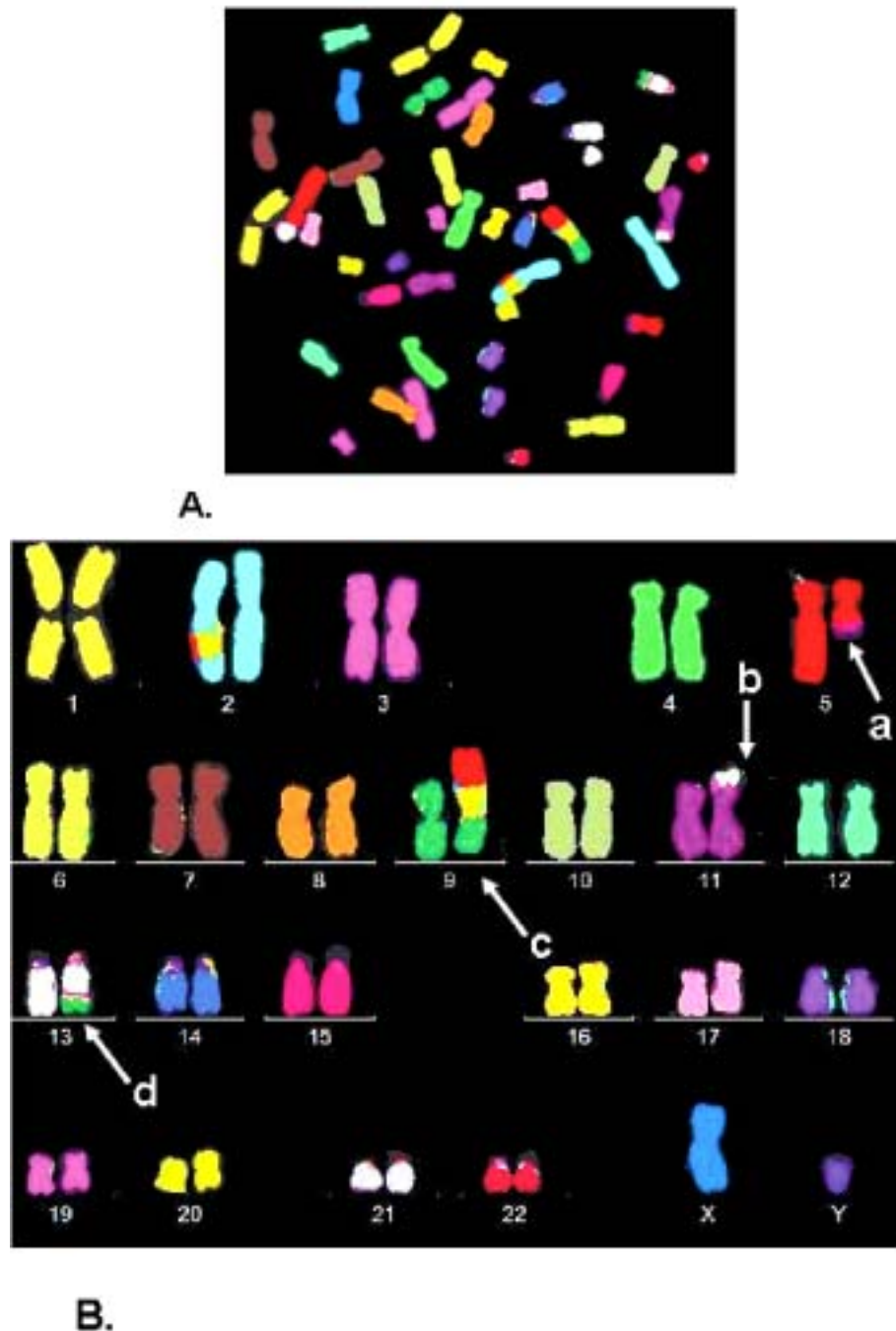


Fig. 5. M-FISH image of congenital heart disease patient with complex variant translocation chromosomes 5, 9, 11 and 13[t(5;9;11;13)(q14;p24;p15;q33)]: (A) Metaphase, and (B) Karyotype of the above metaphase showing (a) chromosome 5 with a part of chromosome 11; (b) chromosome 11 with subtelomeric region of chromosome 13; (c) chromosome 9 with part of chromosome 5q; (d) chromosome 13 with part of chromosome 9p.

This is a case of de novo origin as none of the family members showed the presence of this particular chromosomal aberration. The clinical feature of the proband which includes CHD, and hearing impairment does not fit into the frame of any particular syndrome. However, there have been reports of gene mutations on chromosome 9 as the primary cause of hearing impairment and chromosome 5 as the probable cause of CHD. In our investigation, this is the third case involving chromosome 9 which is con-firming that the chromosome 9 indeed consists of some gene/s required for normal heart develop-ment.

Thus, the present findings are the maiden report from Mysore, which have contributed richly towards the association of chromosomal anomalies with CHD and pointing out chromosome 9 a possible killer chromosome for the cause of CHD.

ACKNOWLEDGMENTS

We thank the patients and their family members who have taken part in the present study. We thank the University of Mysore; DST for providing FIST grants to Department of Zoology; Chairman, DOS in Zoology for giving us (SR) an opportunity to carry out our research activities. Prof. H. A. Ranganath for his encouragement, Dr. Ilse Chudoba (Metasystem, Germany), Dr. Mikhil N. Bamne and Dr. Pushpa Saviour who have rendered their help for this study.

REFERENCES

- Ahmed I, Ghafoor T, Samore NA, Chattha MN 2005. Down syndrome: Clinical and cytogenetic analysis. *J Coll Physicians Surg Pak*, 15(7): 426-429.
- Back E, Toder R, Voiculescu I, Wildberg A, Schempp W 1994. *De novo* isochromosome 18p in two patients: Cytogenetic diagnosis and confirmation by chromosome painting. *Clin Genet*, 45: 301-304.
- Bandyopadhyay R, McCaskill C, Knox-Du Bois C, Zhou Y, Berend SA, Bijlsma E, Shaffer LG 2003. Mosaicism in a Patient with Down syndrome Reveals Post-Fertilization Formation of a Robertsonian Translocation and Isochromosome. *Am J Med Genet A*, 116: 159-163.
- Baruch AC, Erickson RP 2001. Axenfeld-Rieger anomaly, hypertelorism, clinodactyly and cardiac anomalies in sibs with an unbalanced translocation der(6)t(6;8). *Am J Med Genet*, 100(3):187-190.
- Behrman RE, Kliegman RM, Jenson HB 2000. From Congenital heart disease. In: RE Behrman, RM Kliegman, HB Jenson (Eds.): *Nelson Textbook of Pediatrics*. 16th Edition. Philadelphia: Harcourt Asia Pvt. Ltd., pp. 1362-1363.
- Boby J, Karande SC, Lahiri KR, Jain MK, Kanade S 1994. 9P-Syndrome. *J Postgrad Med*, 40(1): 40-41.
- Davalos IP, Rivas F, Ramos AL, Galaviz C, Sandoval L, Rivera H 2000. inv(9)(p24q13) in three sterile brothers. *Annales de Genetique*, 43: 51-54.
- De Vries BBA, Winter R, Schinzel A, Van Ravenswaaij-Arts C 2003. Telomeres: adiagnosis at the end of the chromosomes. *J Med Genet*, 40: 385-398.
- Ergun MA, Balci S, Konac E, Kan D, Menevse S, Bartsch O 2004. Trisomy of 8q22.3 approximately q23-pter following an unbalanced1;8 translocation in a boy with multiple anomalies. *Turk J Pediatr*, 46(4): 348-347.
- Ferencz C, Neill CA, Boughman JA, Rubin JD, Brenner JJ, Perry LW 1989. Congenital cardiovascular malformations associated with chromosome abnormalities: An epidemiologic study. *J Pediatr*, 114(1): 79-86.
- Fisch H, Hyun, Golden R, Hensle TW, Olsson CA, Liberson GL 2003. The influence of paternal age on Down syndrome. *J Urol*, 169(6):2275-2278.
- Gardner RJM and Sultherland GR 1996. Chromosome abnormalities and genetic counseling. *Oxf Monogr Med Genet*, 29: 139-152.
- Grech V, Gatt M 1999. Syndromes and malformations associated with congenital heart disease in a population-based study. *Int J Cardiol*, 28; 68(2):151-156.
- Humphray SJ, Oliver K, Hunt AR, Plumb RW, Loveland JE, Howe KL 2004. DNA sequence and analysis of human chromosome 9. *Nature*, 429(6990): 369-374.
- International System for Human Cytogenetic Nomenclature 2005*. Editor: Felix Mitelman. Basel: Karger.
- Kava MP, Tullu MS, Muranjan MN, Girisha KM 2004. Down Syndrome: Clinical Profile From India. *Archiv Med Res*, 35: 31-35.
- Knight SJL, Regan R, Nicod A, Horsley SW, Kearney L, Homfray T, Winter RM, Bolton P, Flint J 1999. Subtle chromosomal rearrangements in children with unexplained mental retardation. *Lancet*, 354: 1676-1681.
- Ko TM, Hsieh FJ, Chang LS, Pan MF, Lee TY 1992. Pericentric inversions of chromosome 9 in Taiwanese fetuses. *J Formos Med Assoc*, 91(4): 473-474.
- Kothare S, Shetty N, Dave U 2002. Maternal age and chromosomal profile in 160 DS cases- Experience of tertiary genetic center from India. *Int J Hum Genet*, 2(1): 49-53.
- Krishna DS, Al-Awadi SA, Farag TI 1992. Pericentric inversion and recombinant aneusomy and other associated chromosomal aberrations: random or non-random. *Am J Hum Genet A*, 51(4): 291 (1146).
- Kunugi H, Lee KB, Nanko S 1999. Cytogenetic findings in 250 schizophrenics: evidence confirming an excess of the chromosomen aneuploidies and pericentric inversion of chromosome 9. *Schizophr Res*, 40: 43-47.
- Malini SS, Ramachandra NB 2006. Influence of advanced age of maternal grandmothers on Down syndrome. *BMC Med Genet*, 7: 4.

- McAuliffe F, Winsor EJ, Chitayat D 2005. Tetrasomy 9p mosaicism associated with a normal phenotype. *Fetal Diagn Ther*, 20(3): 219-222.
- Mokhtar MM 1997. Chromosomal aberrations in children with suspected genetic disorders. *Eastern Mediterranean Health Journal*, 3(1): 114-122.
- Naganuma M, Tsunemoto M, Naito T 1981. Case histories of neonates with congenital heart disease. *Jpn Circ J*, 45(2): 215-220.
- Neas KR, Smith JM, Chia N, Huseyin S, St Heaps L, Peters G, Sholler G, Tzioumi D, Sillence DO, Mowat D 2005. Three Patients with terminal deletions within the subtelomeric region of chromosome 9q. *Am J Med Genet A*, 132 (4): 425-430.
- Nielsen J, Sillesen I 1975. Incidence of chromosome aberrations among 11,148 newborn children. *Hum Genet*, 30: 1-12.
- Noonan JA 1978. Association of congenital heart disease with syndromes or other defects. *Pediatr Clin North Am*, 25: 797-816.
- Official Home page of The Franklin Institute: The Heart: An Online Exploration 2004. From <http://www.fi.edu/biosci/> (Retrieved October 21, 2004).
- Paladini D, Tartaglione A, Agangi A, Teodoro A, Forleo F, Borghese A, Martinelli P 2000. The association between congenital heart disease and Down syndrome in prenatal life. *Ultrasound Obstet Gynecol*, 15(2): 104-108.
- Parmar RC, Sira P 2003. Prenatal diagnosis of partial trisomy 21 associated with maternal balanced translocation 46xx der 21 t(21q;22q) with pericentric inversion of chromosome 9. *J Postgrad Med*, 49: 154-156.
- Patel ZM, Madon P 2004. Interchange trisomy 22 in a live born resulting from 3:1 segregation in a t(15;22)(p12;q13) carrier mother. *Ind J Pediatr*, 71: 1-3.
- Payne M, Johnson MC, Grant JW, Strauss AW 1995. Towards a molecular understanding of congenital heart disease. *Circulation*, 91: 494-504.
- Prasad C, Chudley AE 2002. Genetics and Cardiac Anomalies: the Heart of the Matter. *Ind J Pediatr*, 69(4): 321-332.
- Riegel M, Baumer A, Suss J, Schinzel A 2005. An unusual reciprocal translocation detected by subtelomeric FISH: interstitial and not terminal. *Am J Med Genet A*, 135(1): 86-90.
- Roskes EJ, Boughman JA, Schwartz S, Cohen MM 1990. Congenital cardiovascular malformations (CCVM) and structural chromosome abnormalities: a report of 9 cases and literature review. *Clin Genet*, 38(3): 198-210.
- Scarinci R, Anichini C, Vivarelli R, Berardi R, Pucci L, Rosaia L, Tomaccini D 1992. Correlation of the clinical phenotype with a pericentric inversion of chromosome 9. *Boll Soc Ital Biol Sper*, 68(3): 175-181.
- Smith SA, Martin KE, Dodd KL, Young ID 1994. Severe microphthalmia, diaphragmatic hernia and Fallot's tetralogy associated with a chromosome 1;15 translocation. *Clin Dysmorphol*, 3(4): 287-291.
- Smitha R, Gawde HM, Hyderi A, Savitha MR, Patel ZM, Krishnamurthy B, Ramachandra NB 2006a. *De novo* origin of i(18p) in a dysmorphic female child. *J App Genet*, 47(4): 397-340.
- Smitha R, Karat SC, Narayanappa D, Krishnamurthy B, Prasanth SN, Ramachandra NB 2006b. Prevalence of Congenital Heart Diseases in Mysore. *Ind J Hum Genet*, 12(1): 12-17.
- Smitha R, Savitha MR, Krishnamurthy B, Doddaiiah N, Prasanth SN, Ramachandra NB 2007. Association between pericentric inversion in chromosome 9 and congenital heart defects. *Int J Hum Genet*, 7(3): 241-248.
- Soares G, Alvares S, Rocha C, Teixeira MF, Mota MC, Reis MI, Feijo MJ, Lima MR, Pinto MR 2005. Congenital heart defects and chromosomal anomalies including 22q11 microdeletion (CATCH 22). *Rev Port Cardiol*, 24(3): 349-371.
- Srebniak M, Wawrzekiewicz A, Wiczowski A, Kazmierczak W, Olejek A 2004. Subfertile couple with inv(2),inv(9) and 16qh+. *J Appl Genet*, 45(4): 477-479.
- Stoll C, Alembik Y, Dott B, Roth MP 1998. Study of Down syndrome in 238,942 consecutive births. *Ann Genet*, 41: 44-51.
- Tank S, Malik S, Joshi S 2004. Epidemiology of Congenital Heart Disease among Hospitalised Patients. *Bombay Hospital J*, 46(2): 10.
- Teo SH, Tan M, Knight L, Ng I 1995. Pericentric inversion 9-incidence and clinical significance. *Ann Acad Med Singapore*, 24: 302-304.
- Tubman TR, Shields MD, Craig BG, Mulholland HC, Nevin NC 1991. Congenital heart disease in Down's syndrome: two year prospective early screening study. *BMJ*, 302: 1425-1427.